

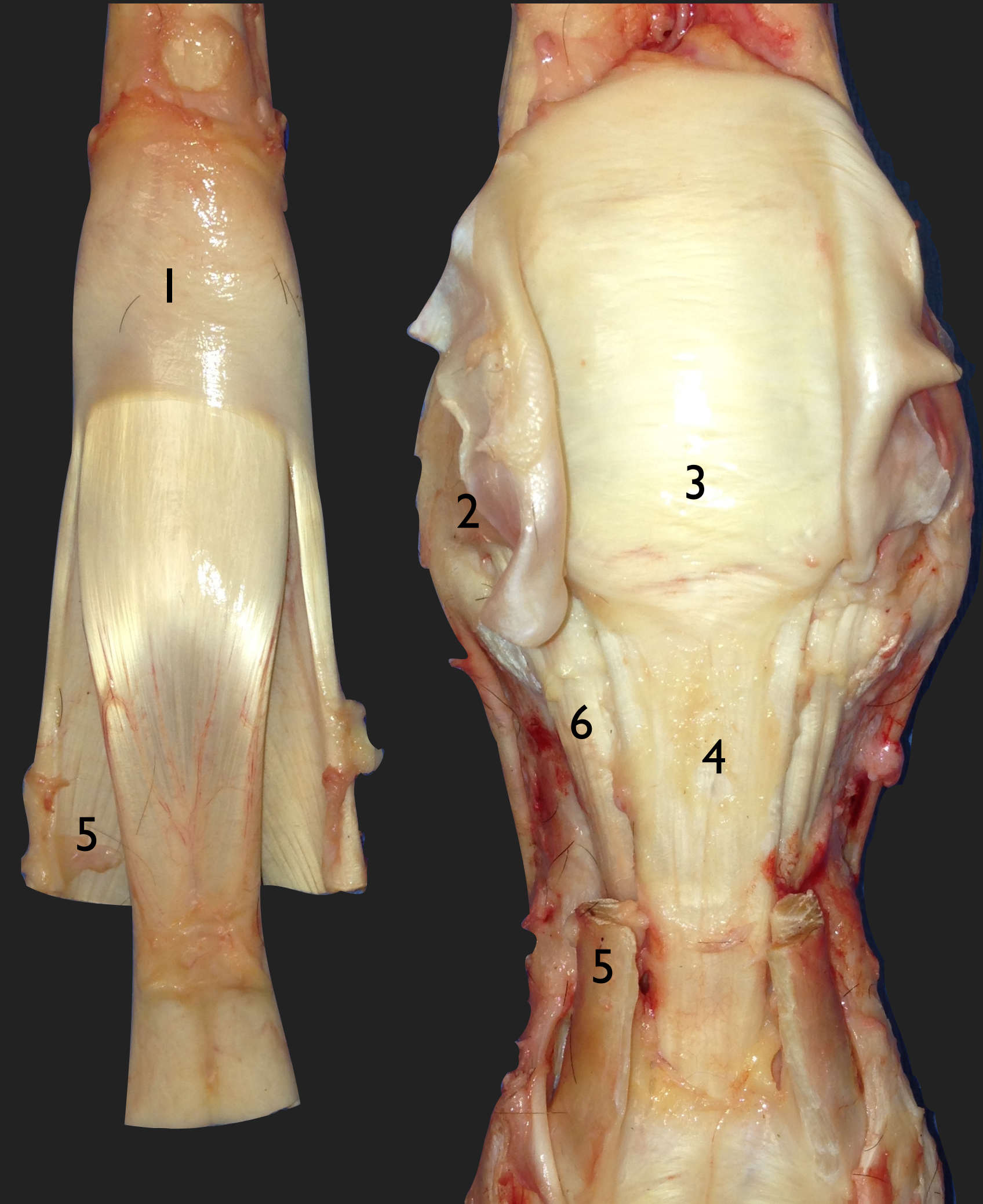
KURT SELBERG

SELBERG@INSIDEINFORMATIONRADIOLOGY.COM

DIGITAL FLEXOR SHEATH

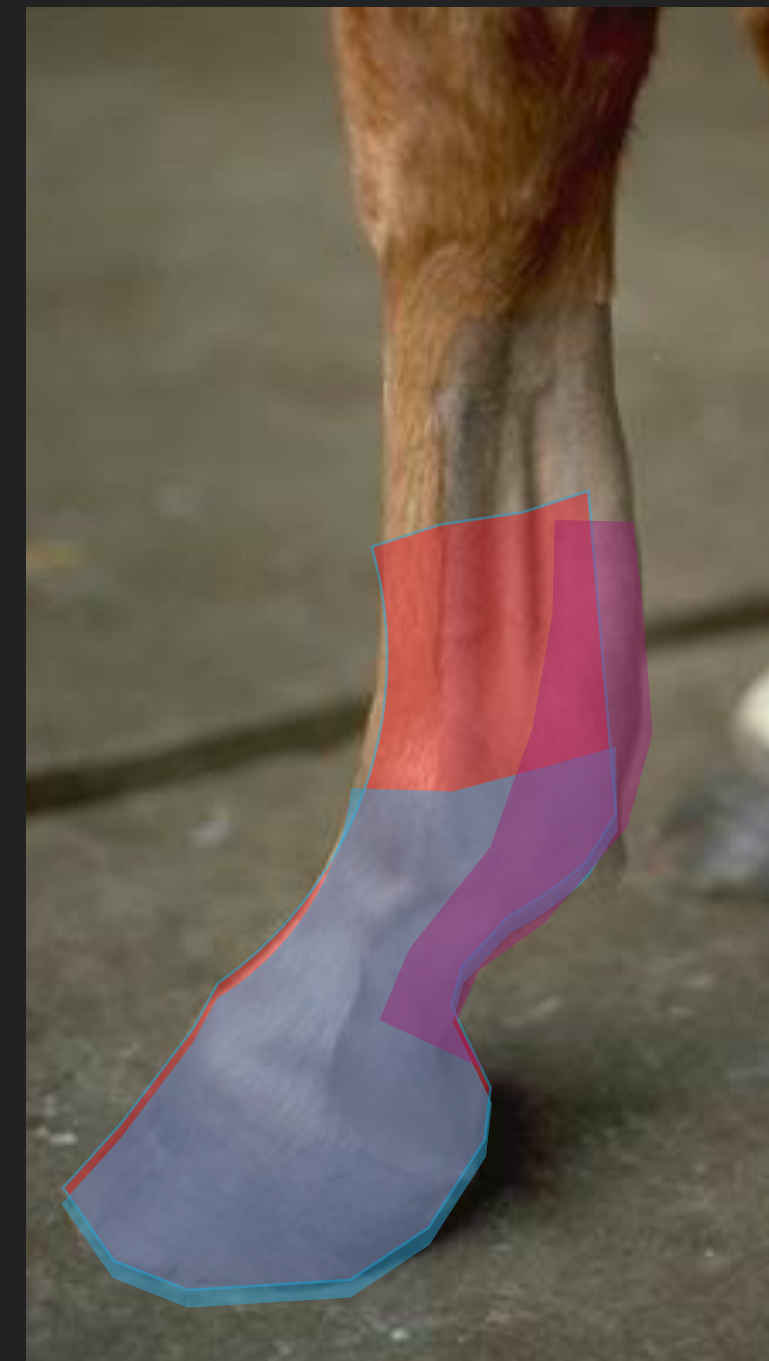PASTERN ANATOMY

1. Manica Flexoria
2. Palmar annular ligament
3. Palmar ligament (intersesamoidean)
4. Straight Sesamoidean ligament
5. Superficial Digital Flexor Tendon
6. Oblique Sesamoidean ligament

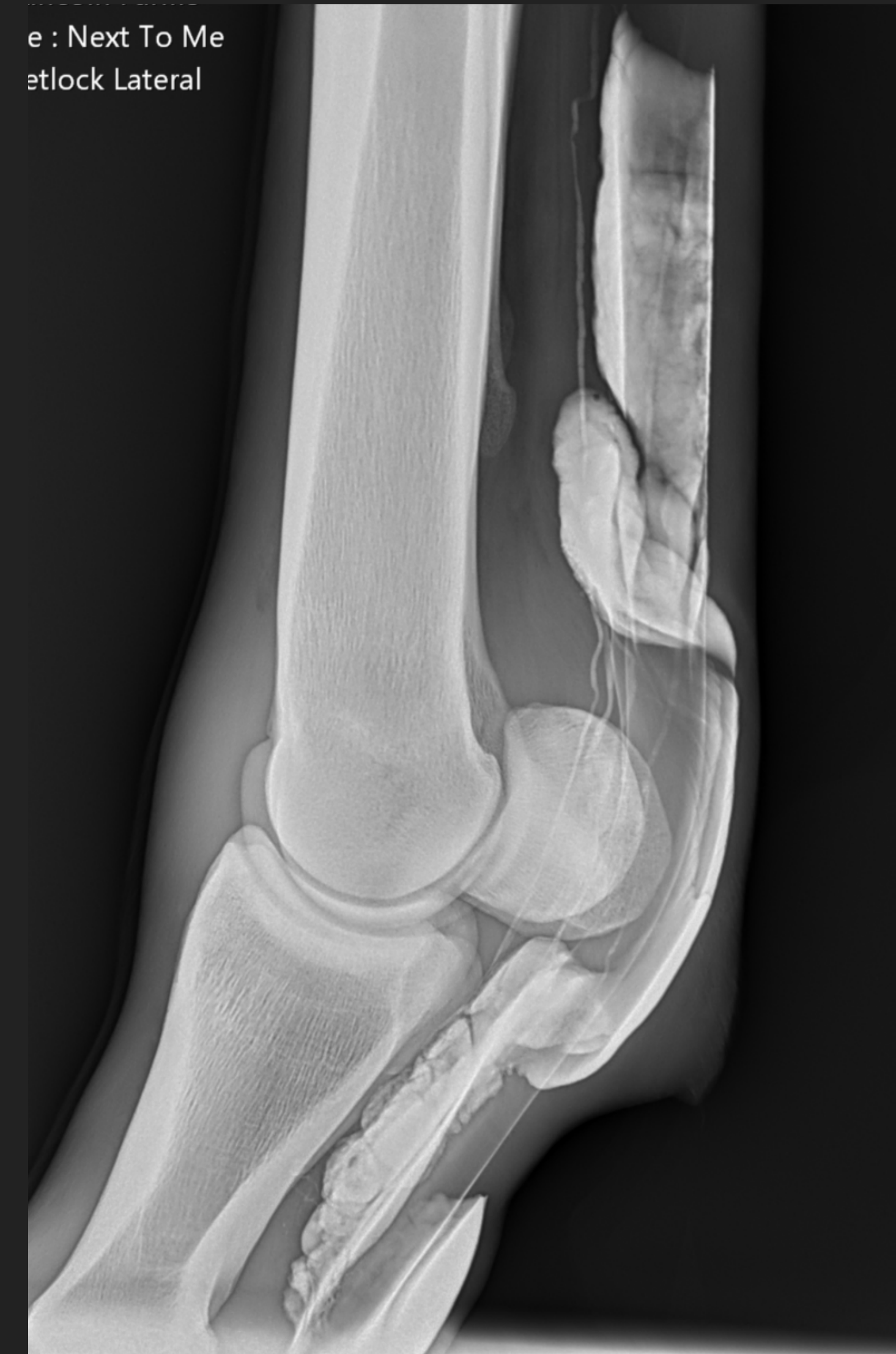

DIGITAL FLEXOR SHEATH

- ▶ Why Image:
 - ▶ Effusion
 - ▶ acute
 - ▶ asymmetric
 - ▶ Blocks to the region
 - ▶ Abnormal palpation
 - ▶ Suspected injury
 - ▶ Recheck

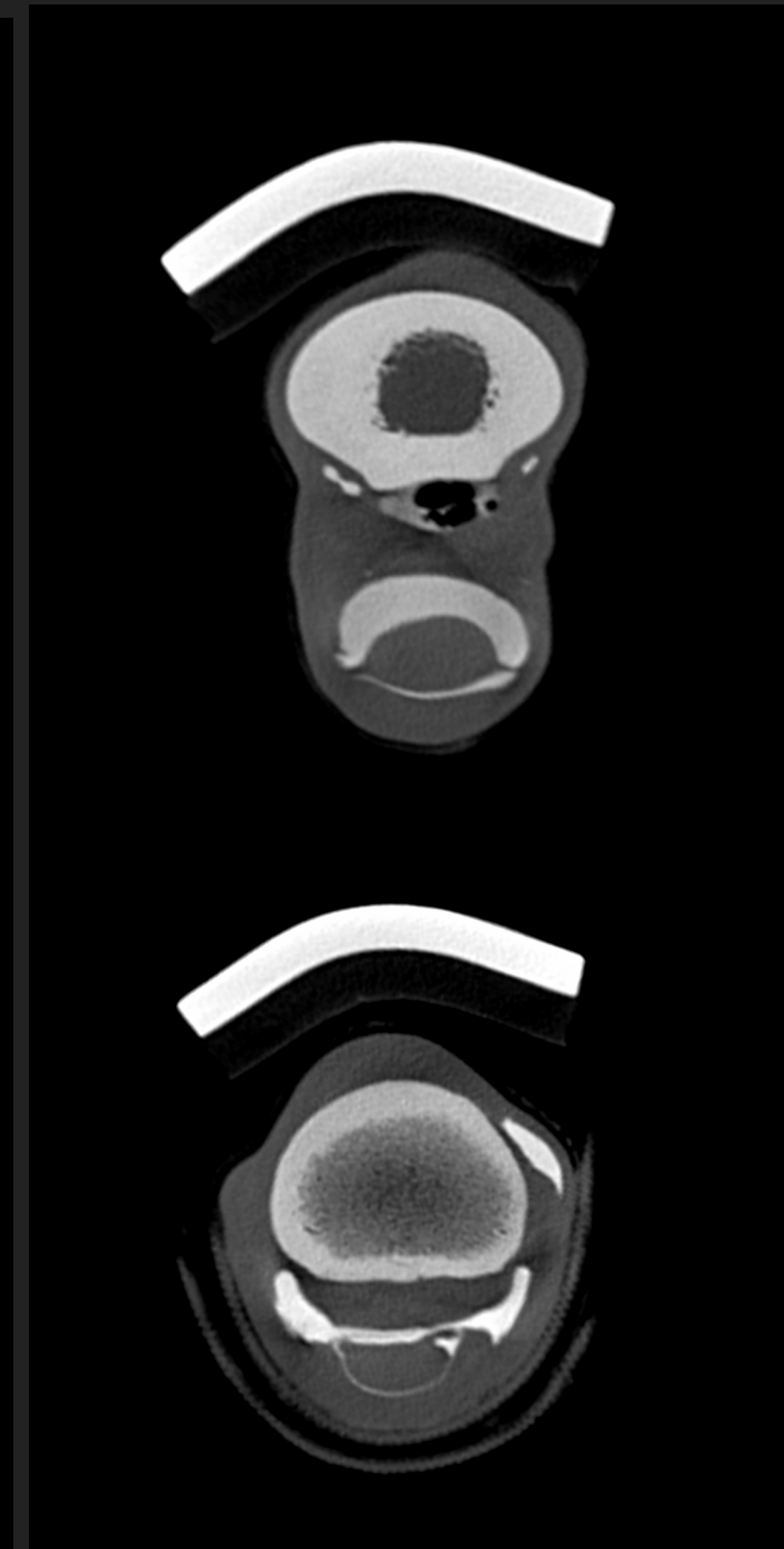
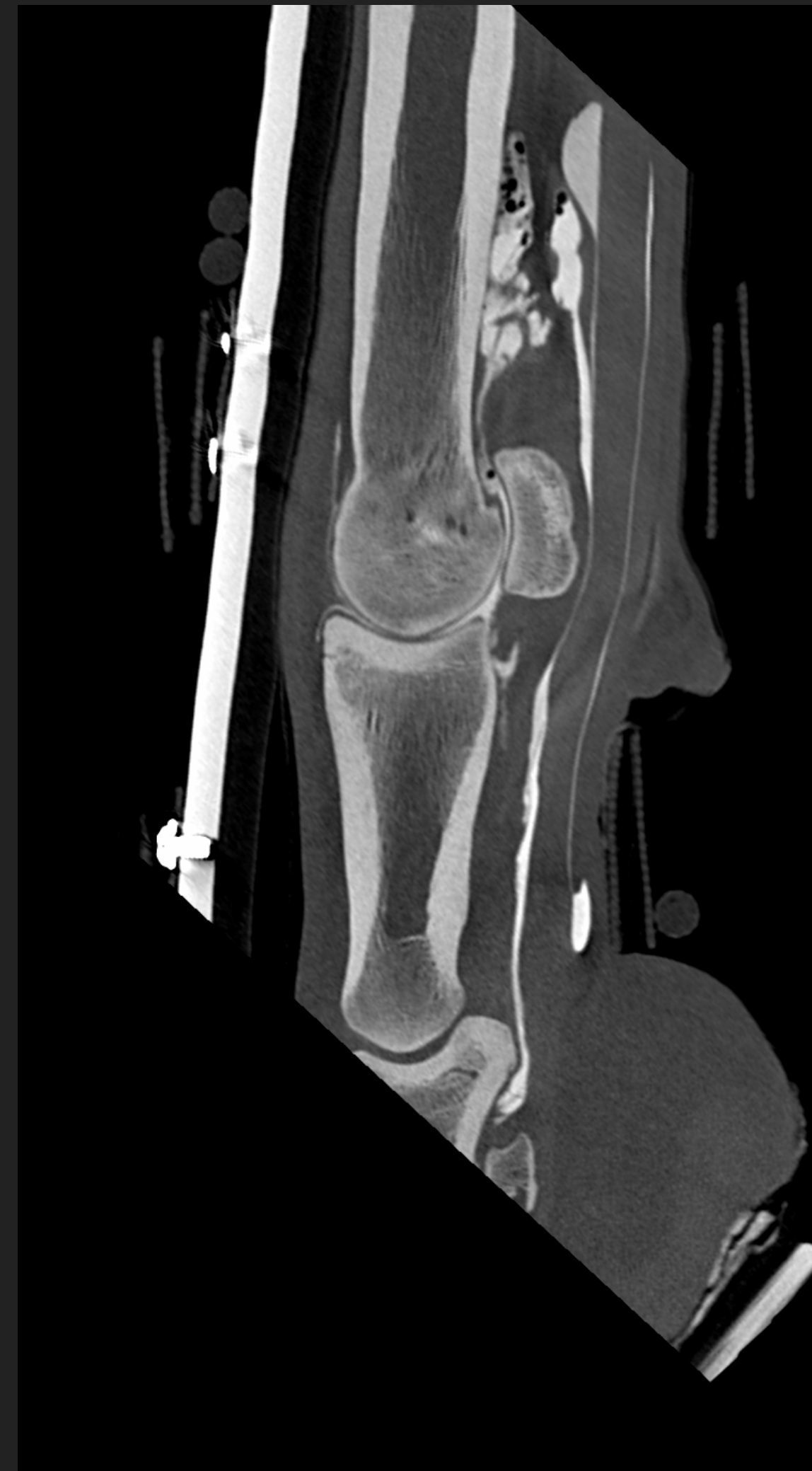

e : Next To Me
etlock Lateral

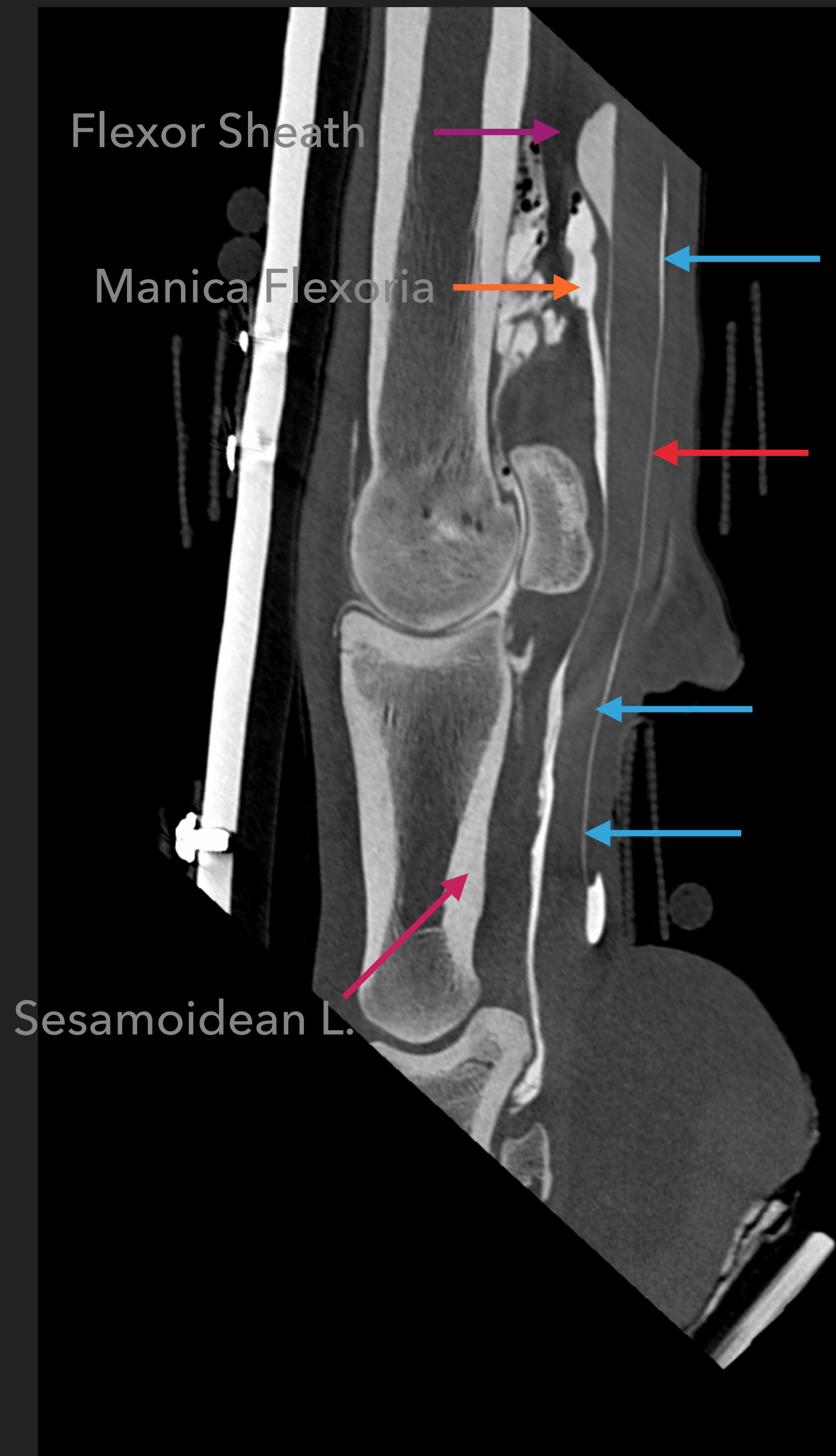


CHECKLIST

- ▶ Deep digital flexor tendon
- ▶ Superficial digital flexor tendon
- ▶ Manica flexoria
- ▶ Distal sesamoidean ligaments
- ▶ Annular ligaments
 - ▶ Palmar/plantar
 - ▶ Proximal/distal annular ligament
- ▶ Intersesamodean ligament
- ▶ Digital flexor sheath
- ▶ Vinculum- blood flow

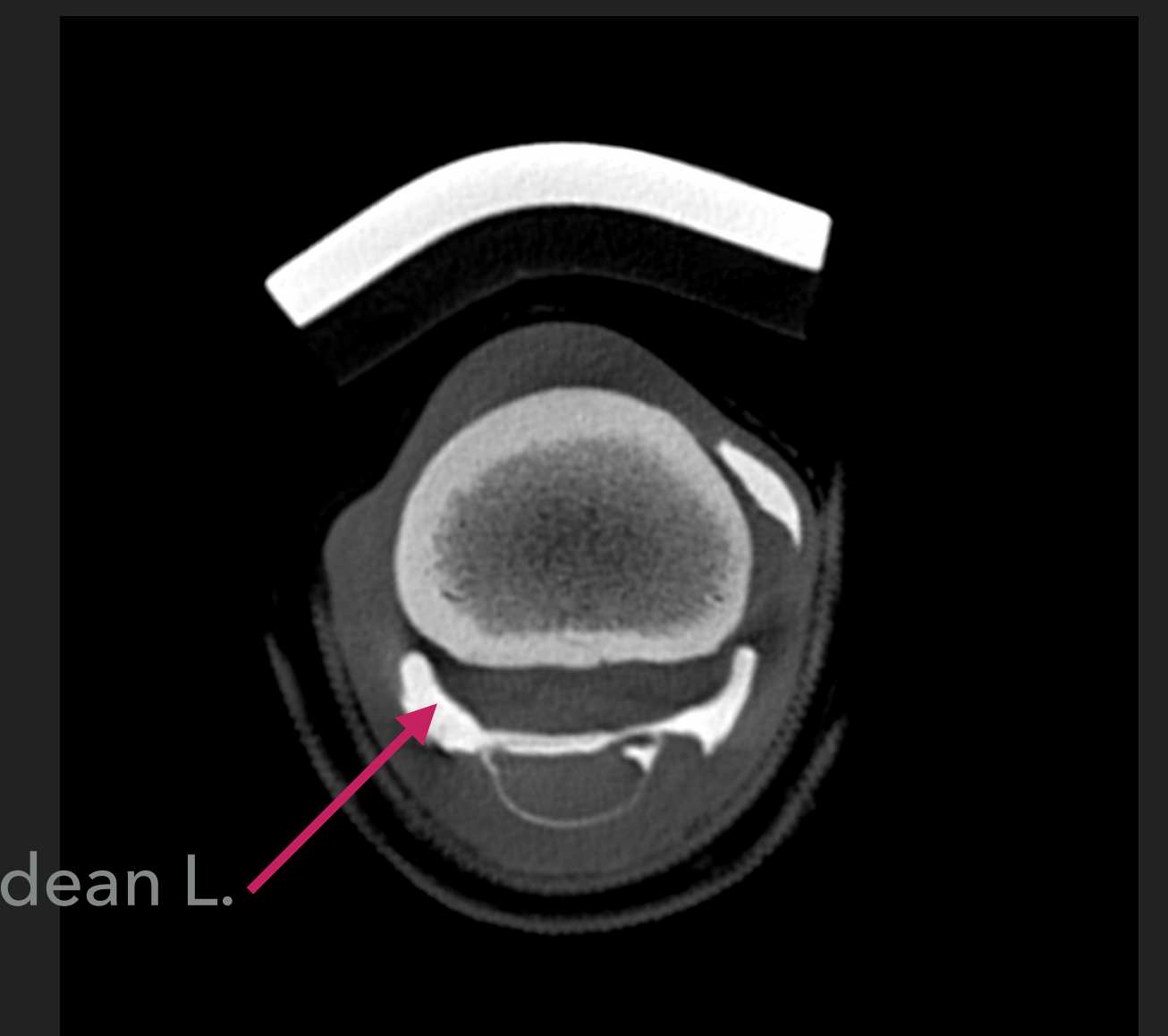
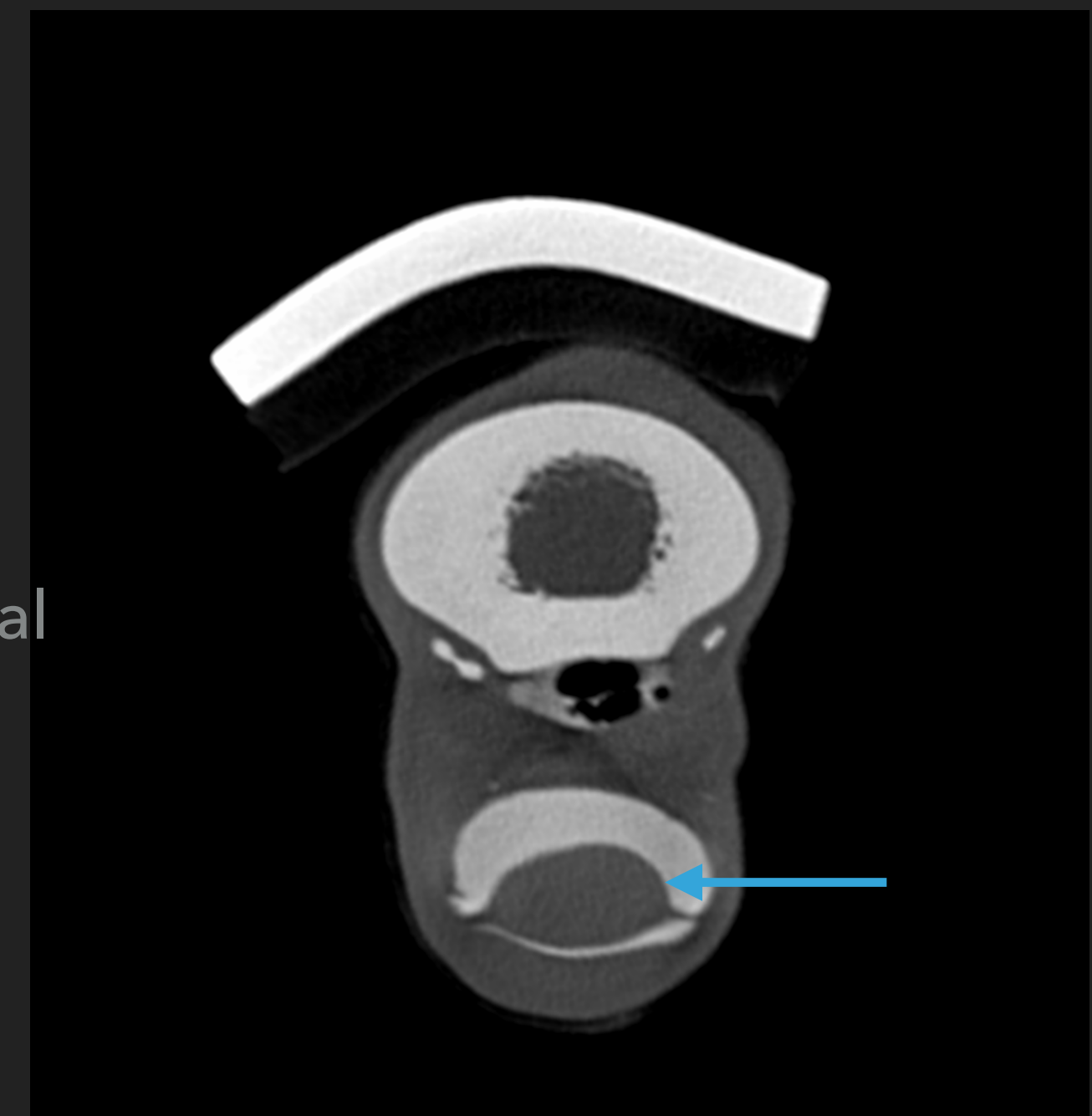


CHECKLIST

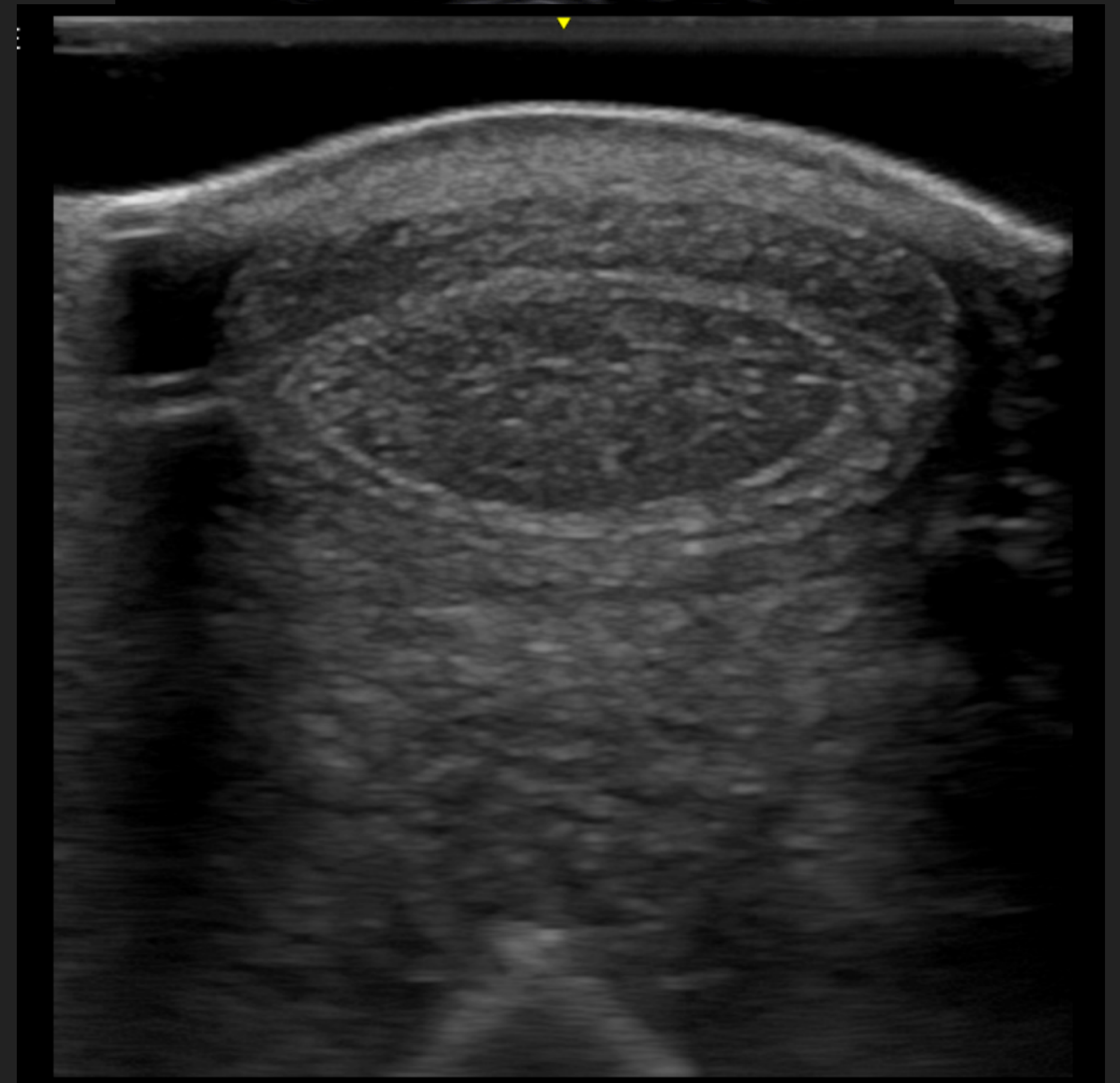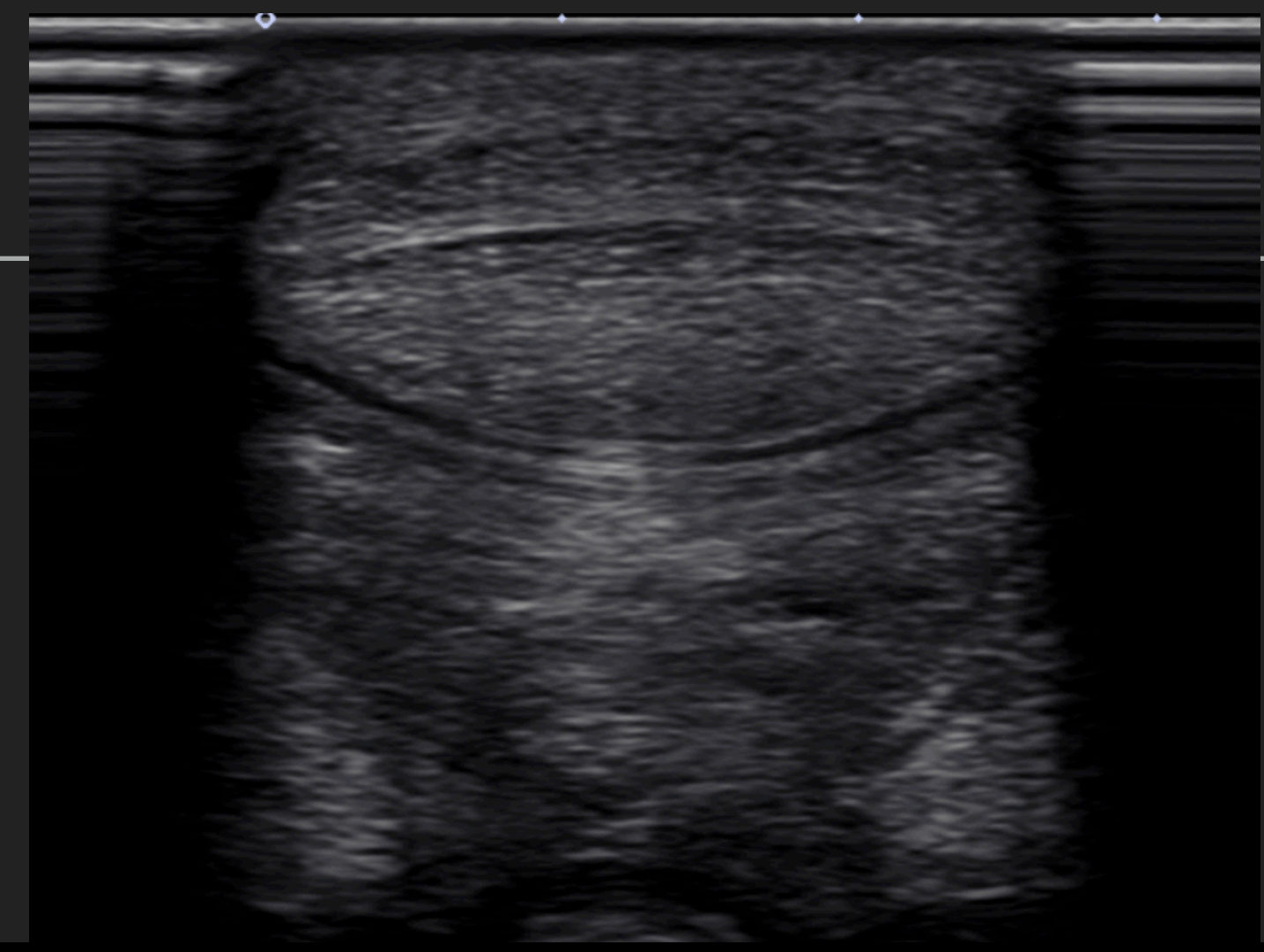
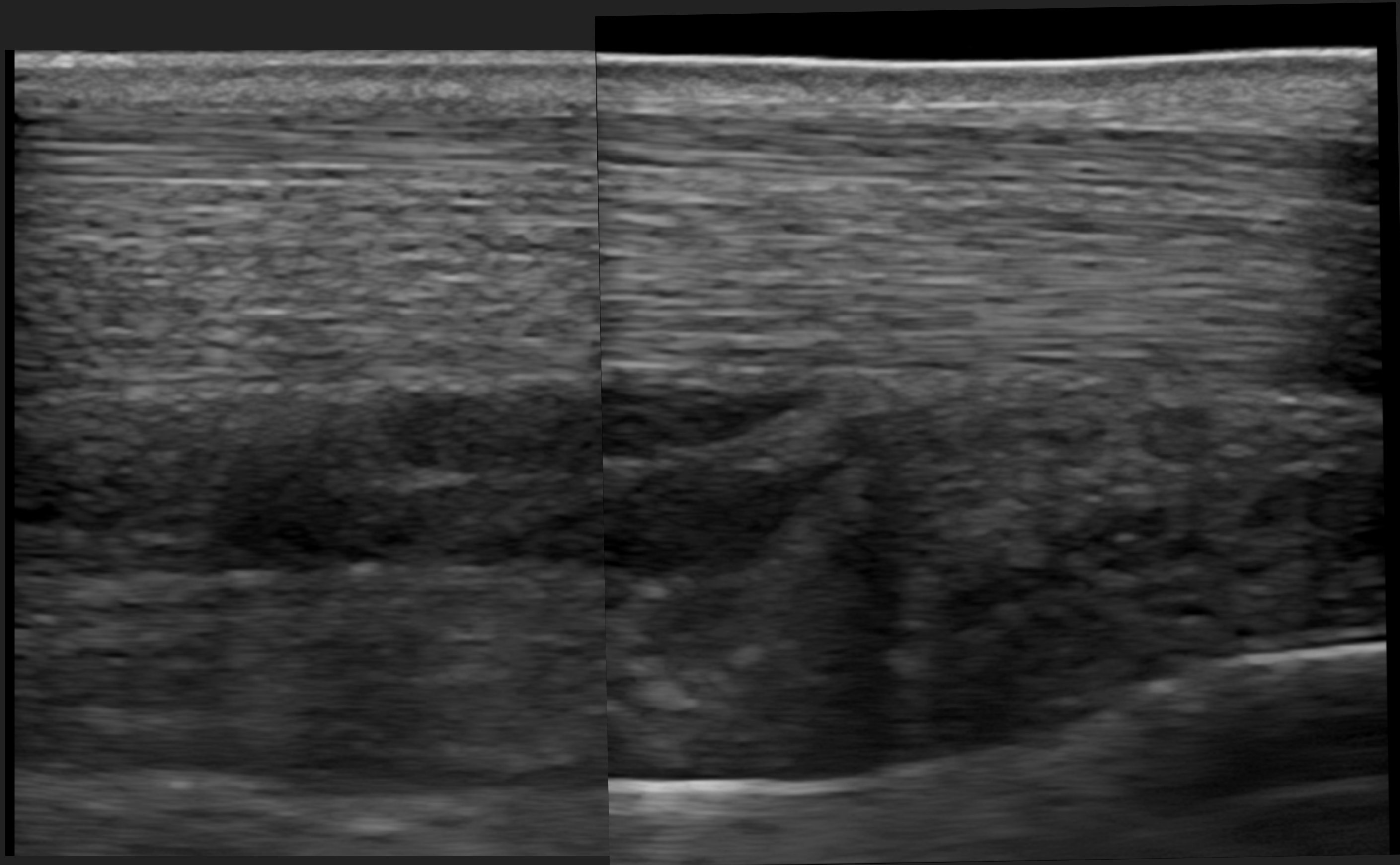


deep digital flexor tendon

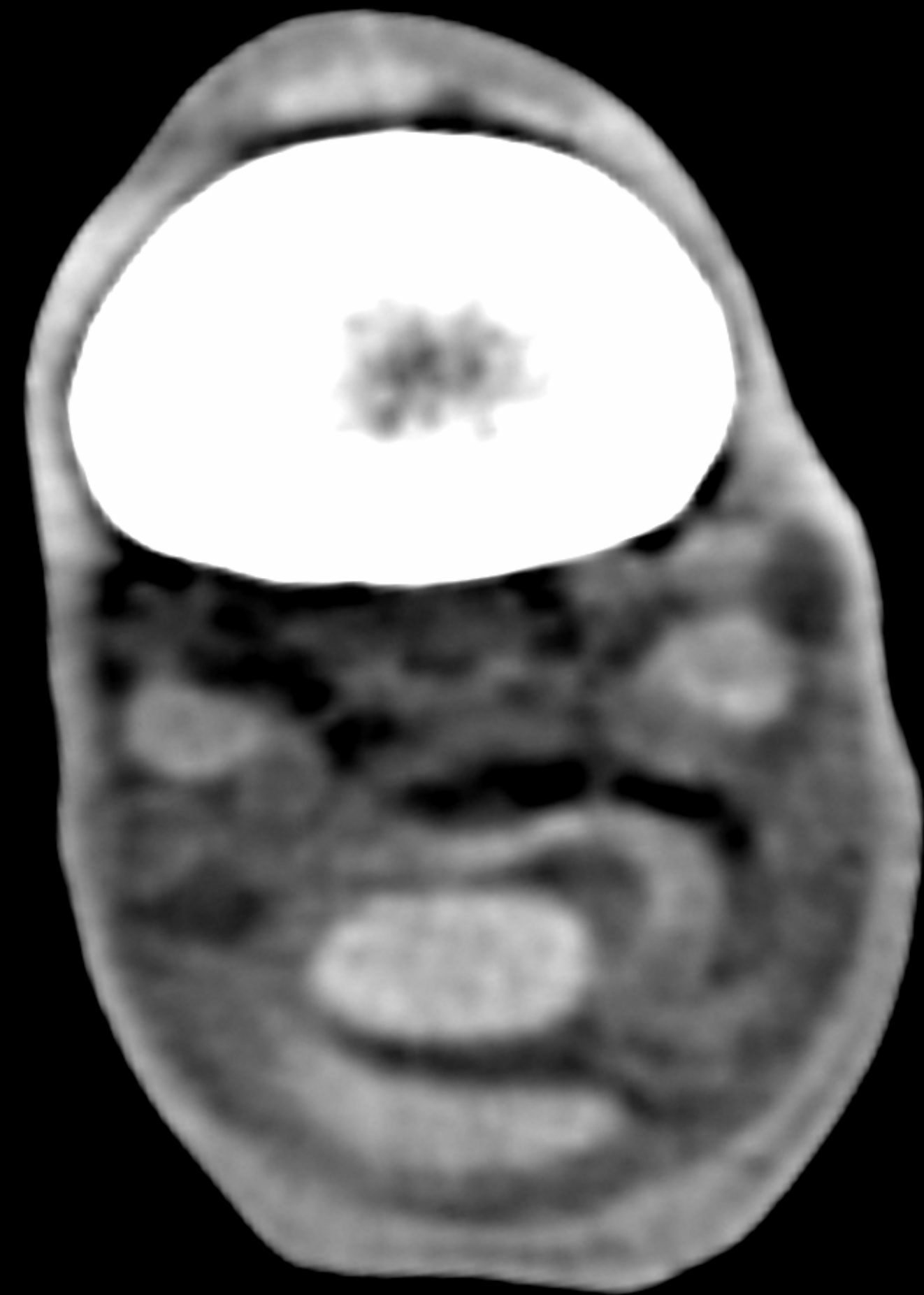
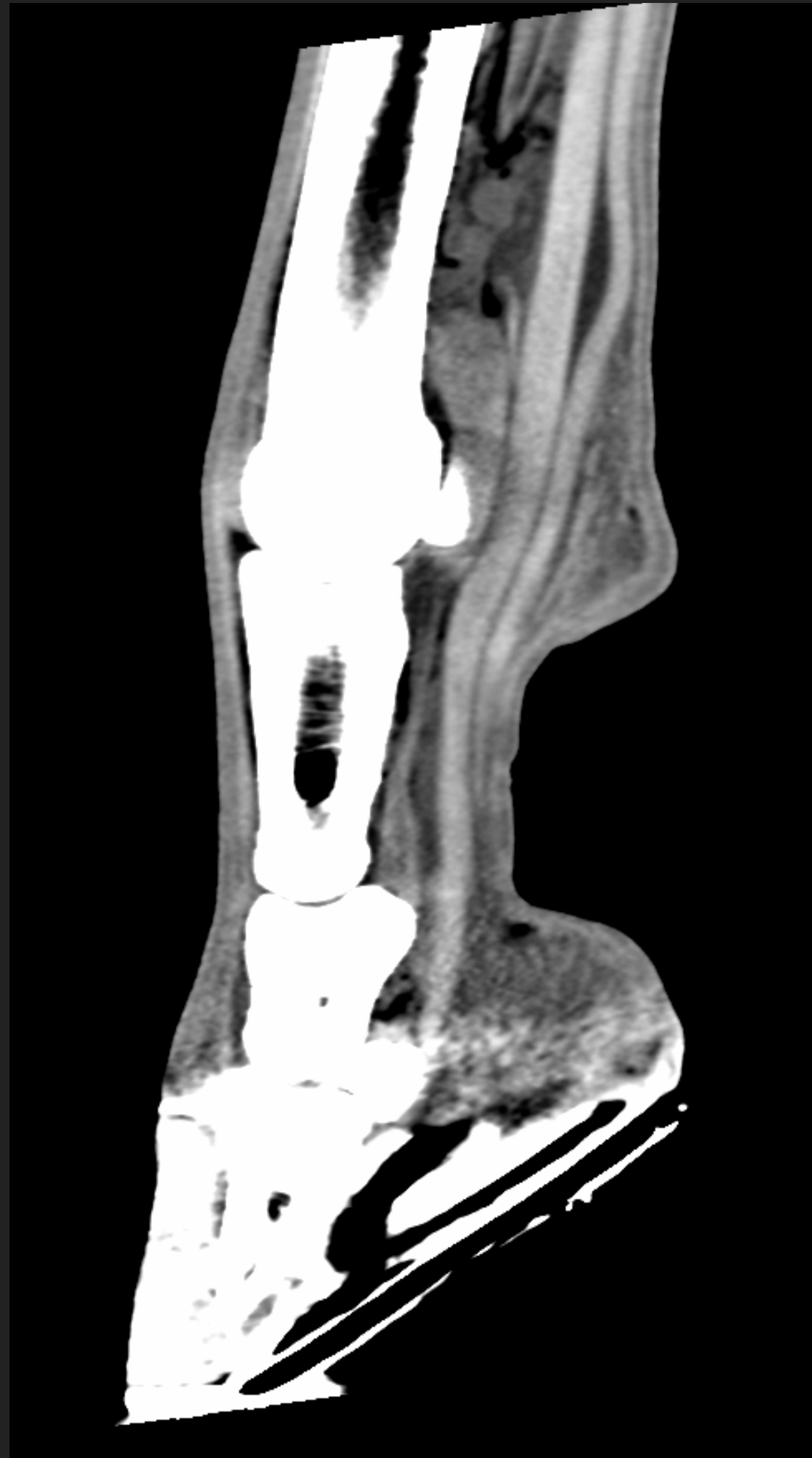superficial digital flexor tendon



MANICA FLEXORIA



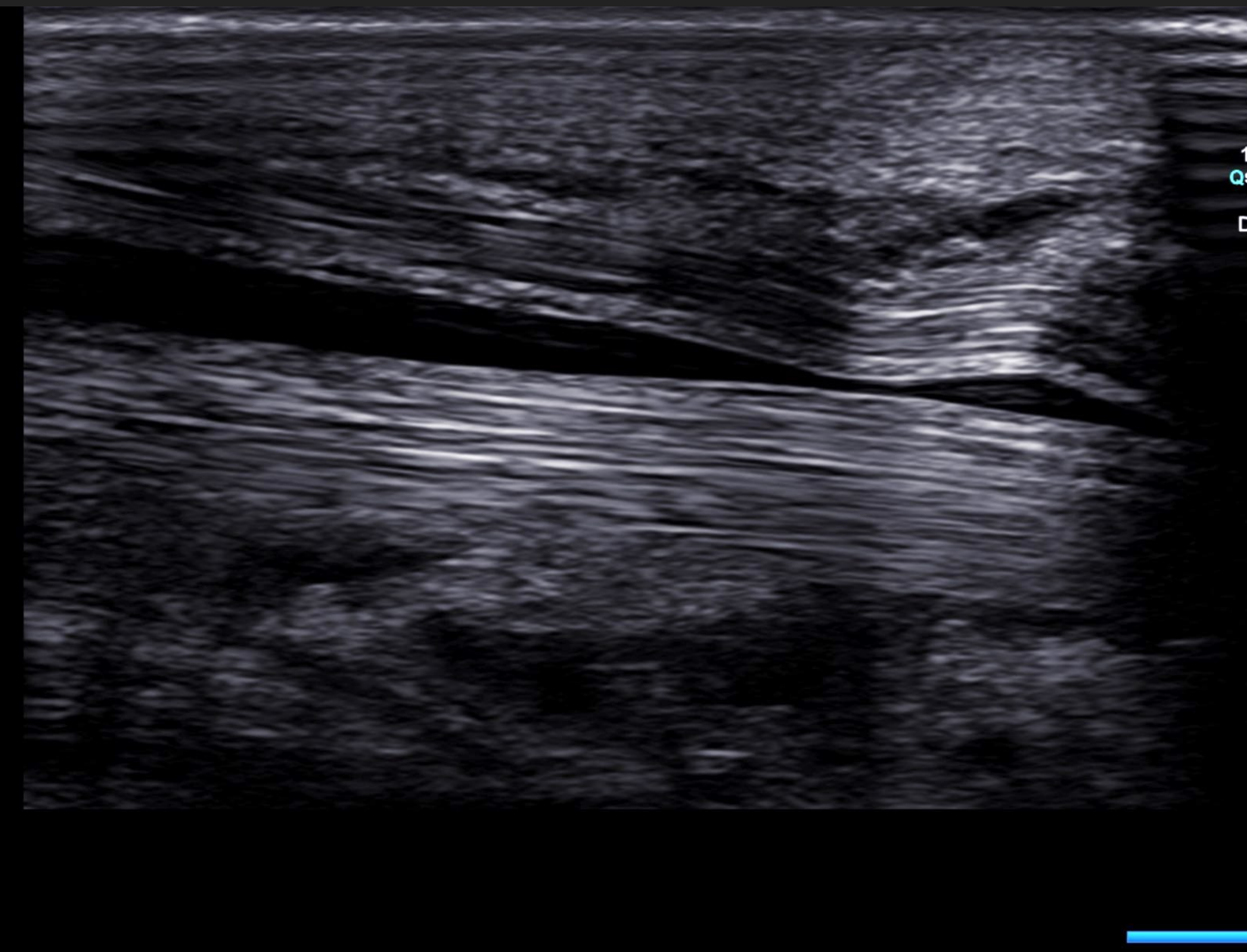
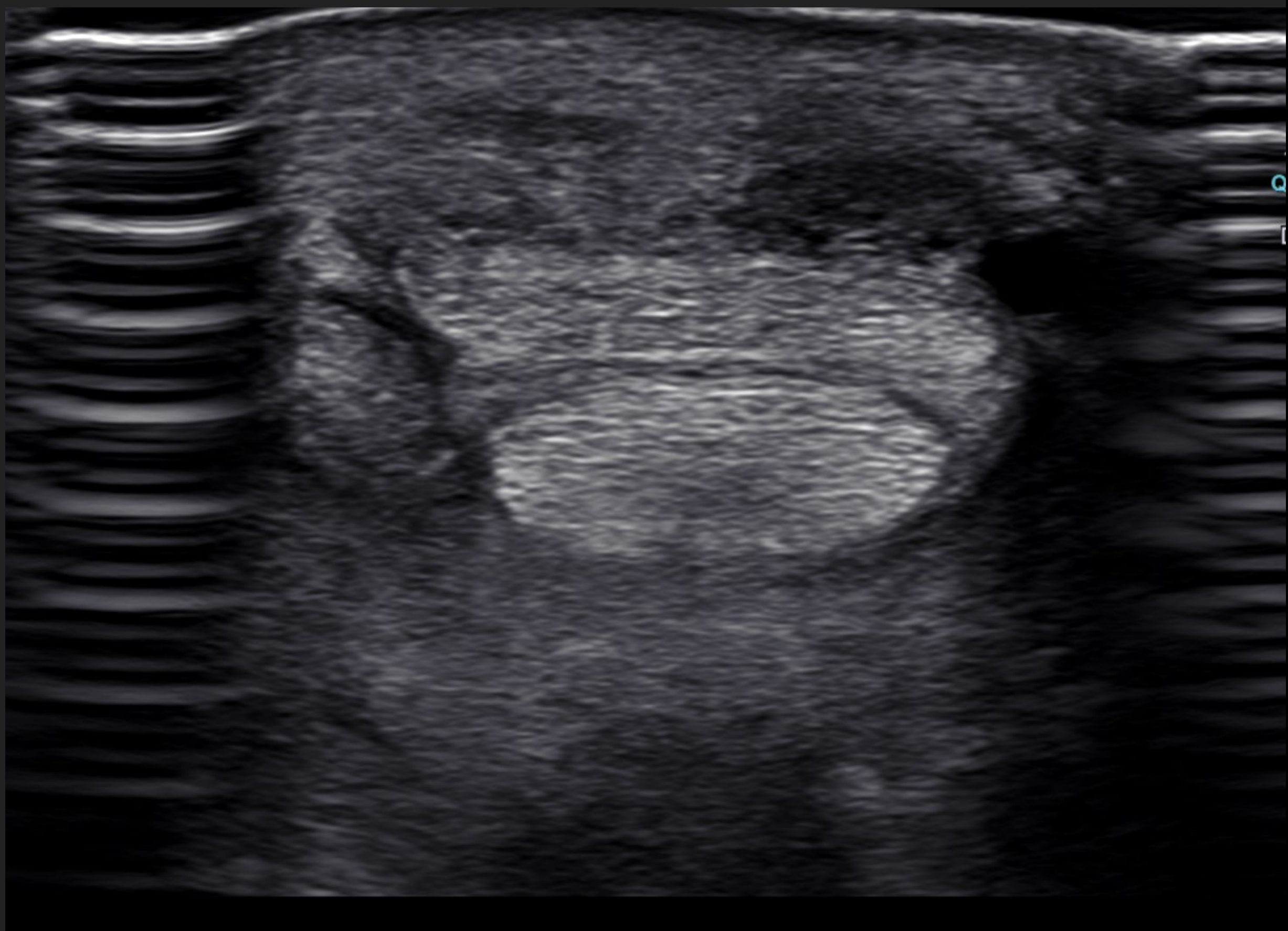
MANICA FLEXORIA



15 YO WB Jumper

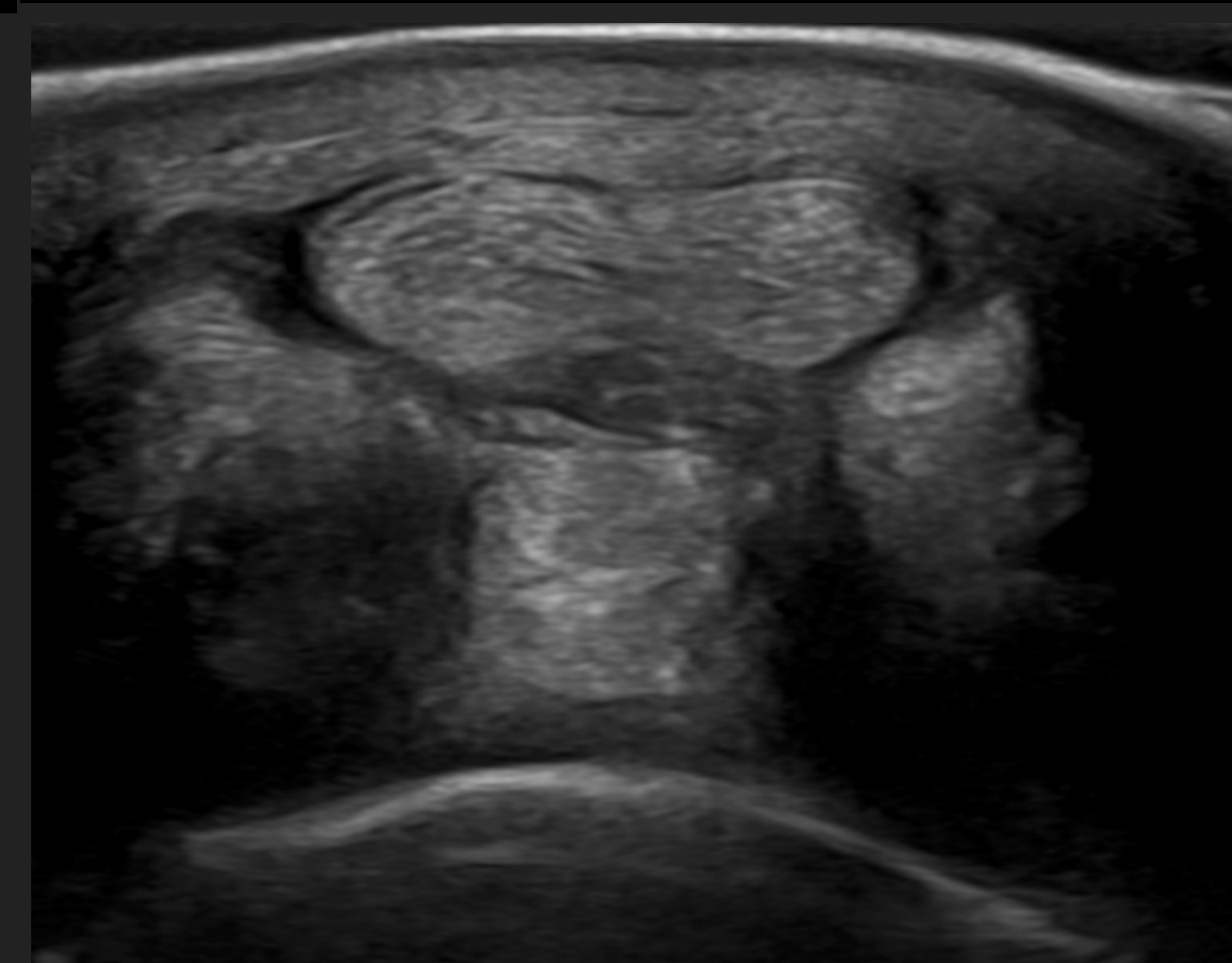
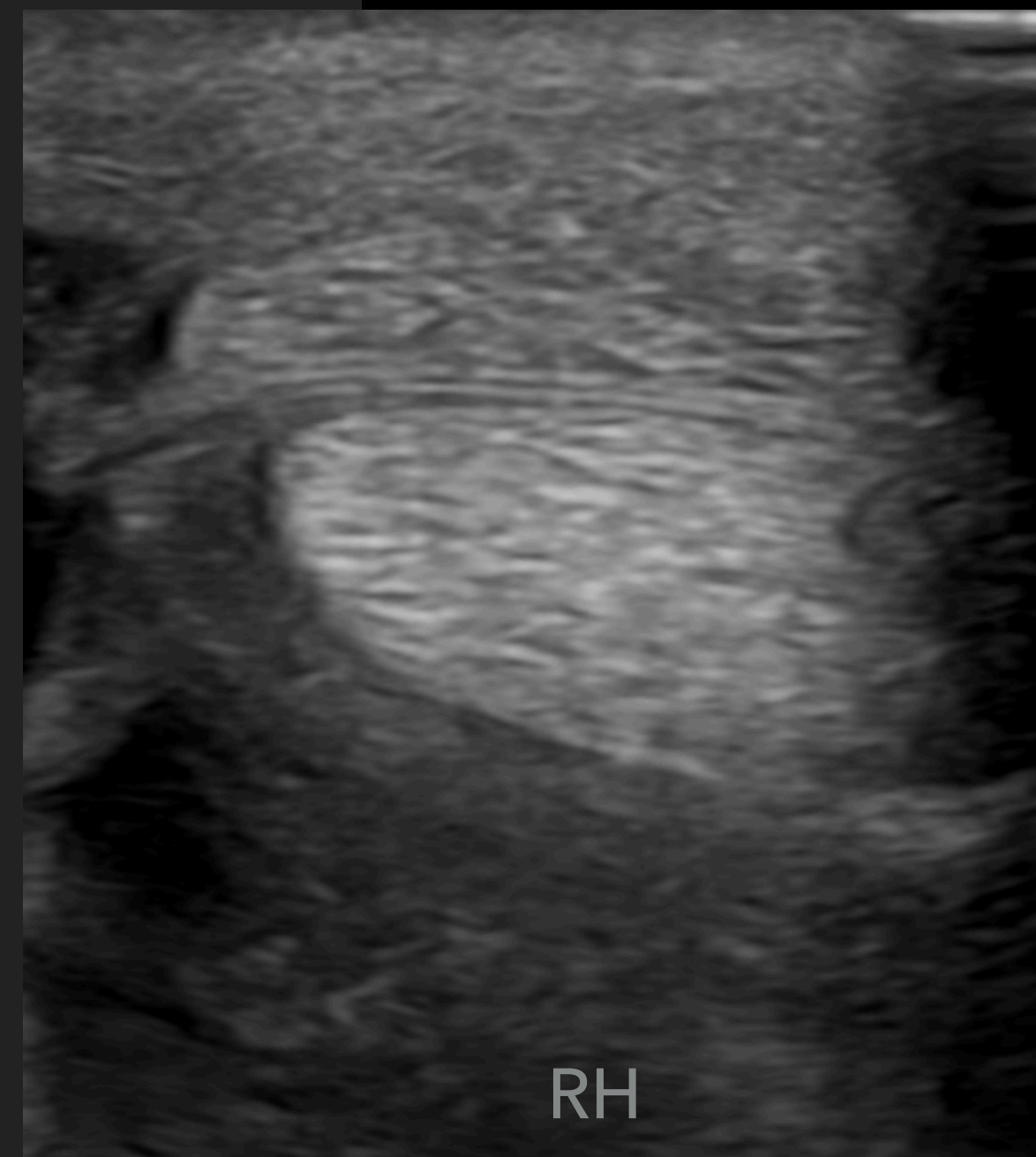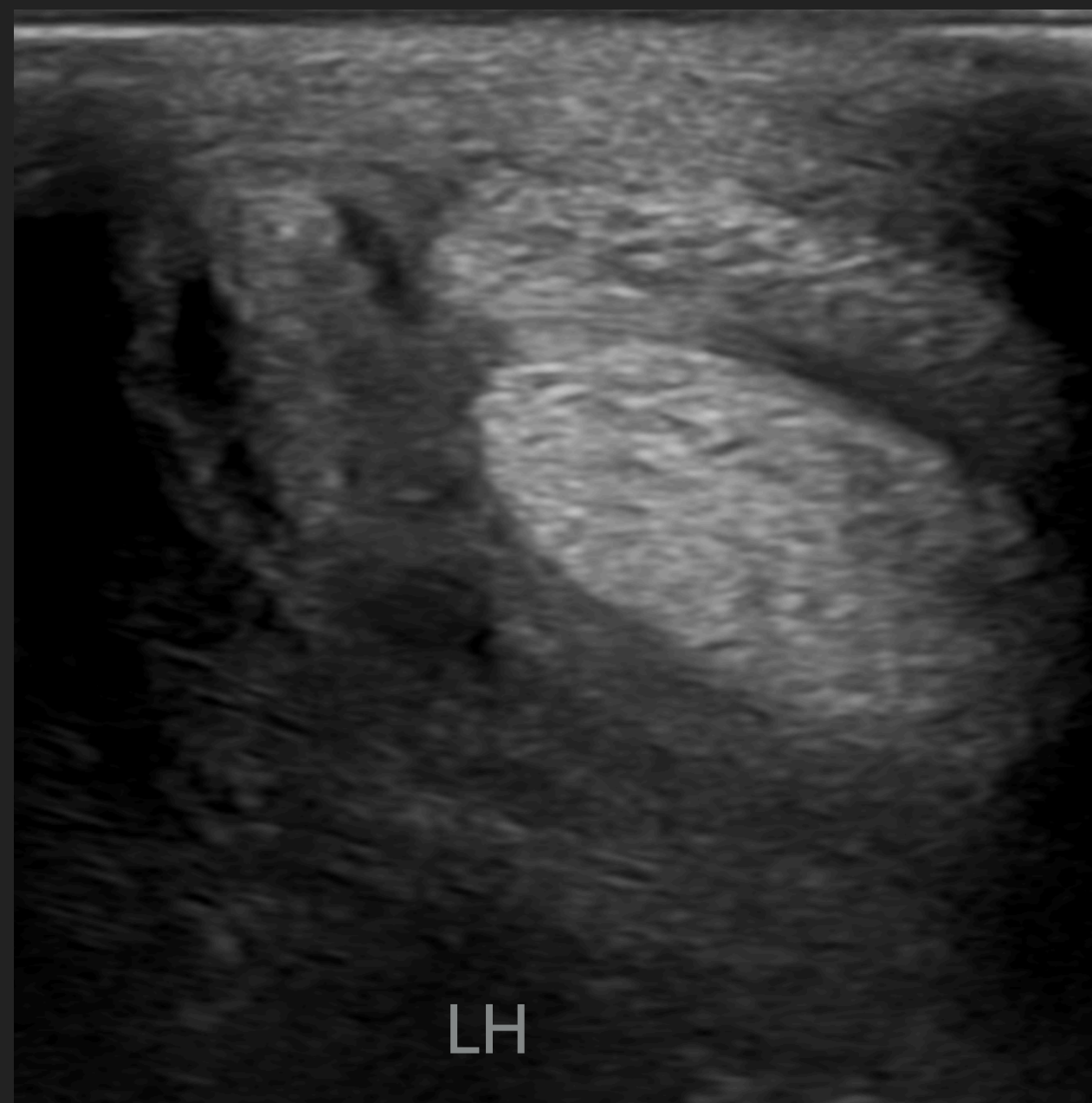
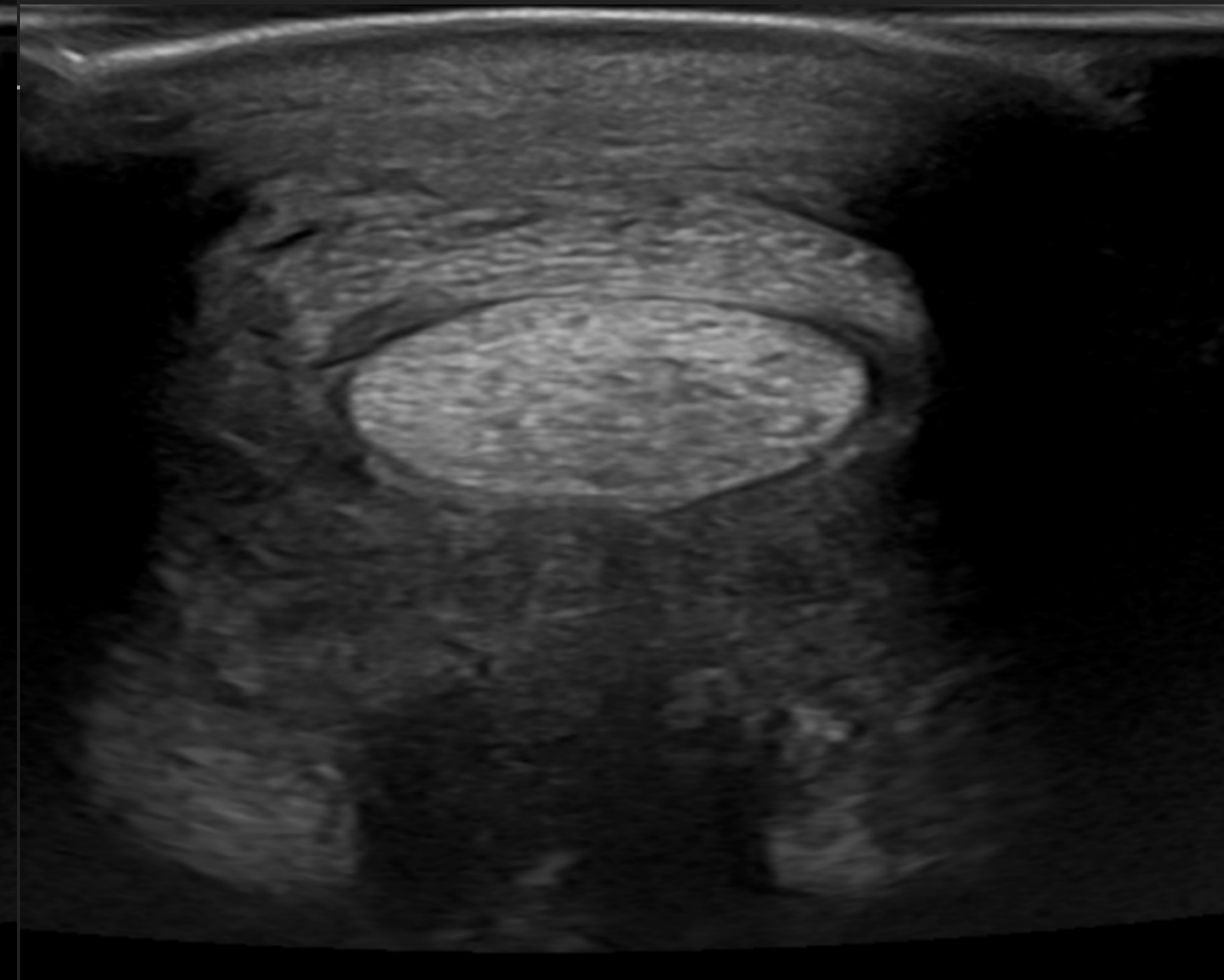
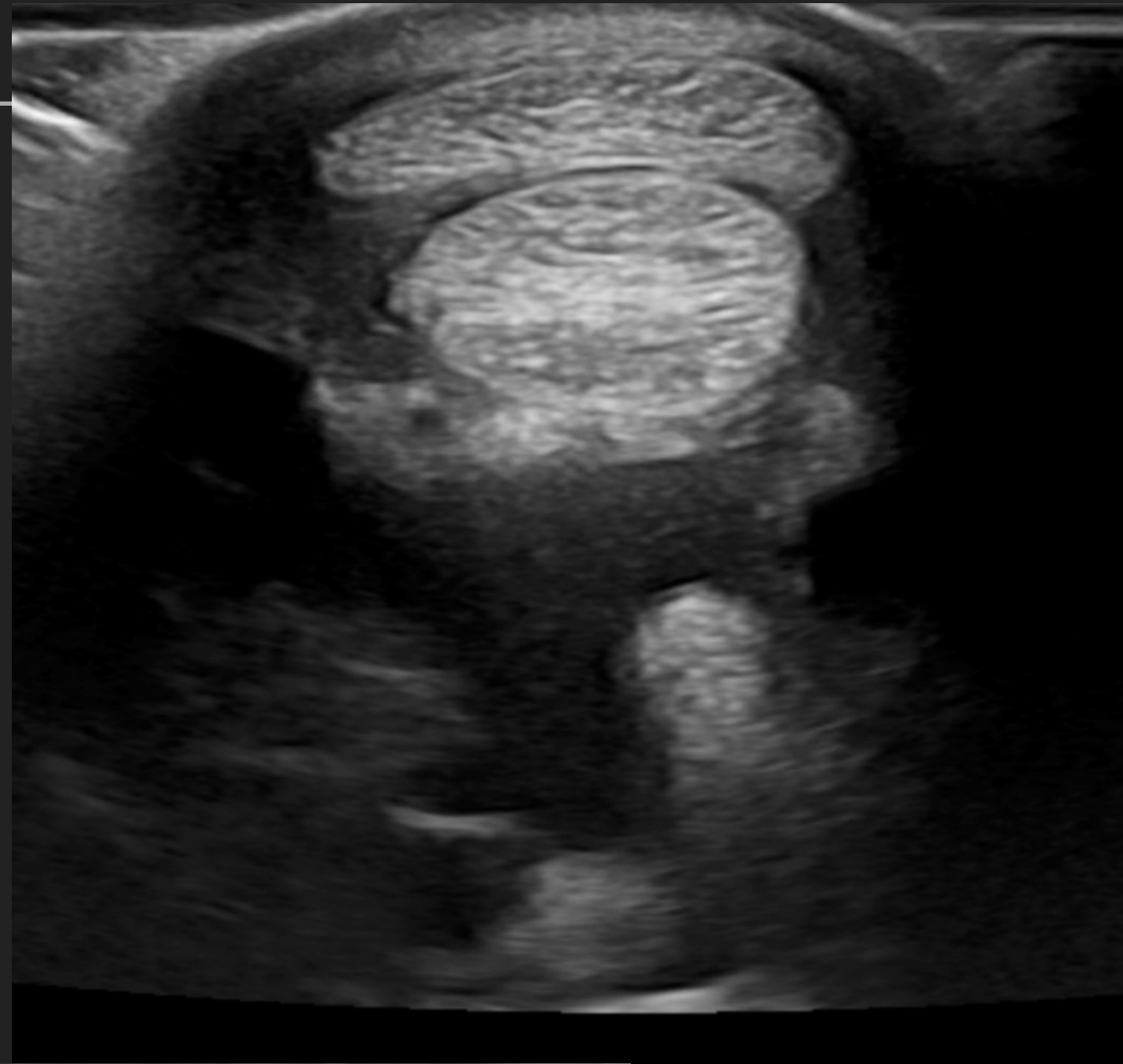
MANICA FLEXORIA

7 YO



18 YO MUSTANG

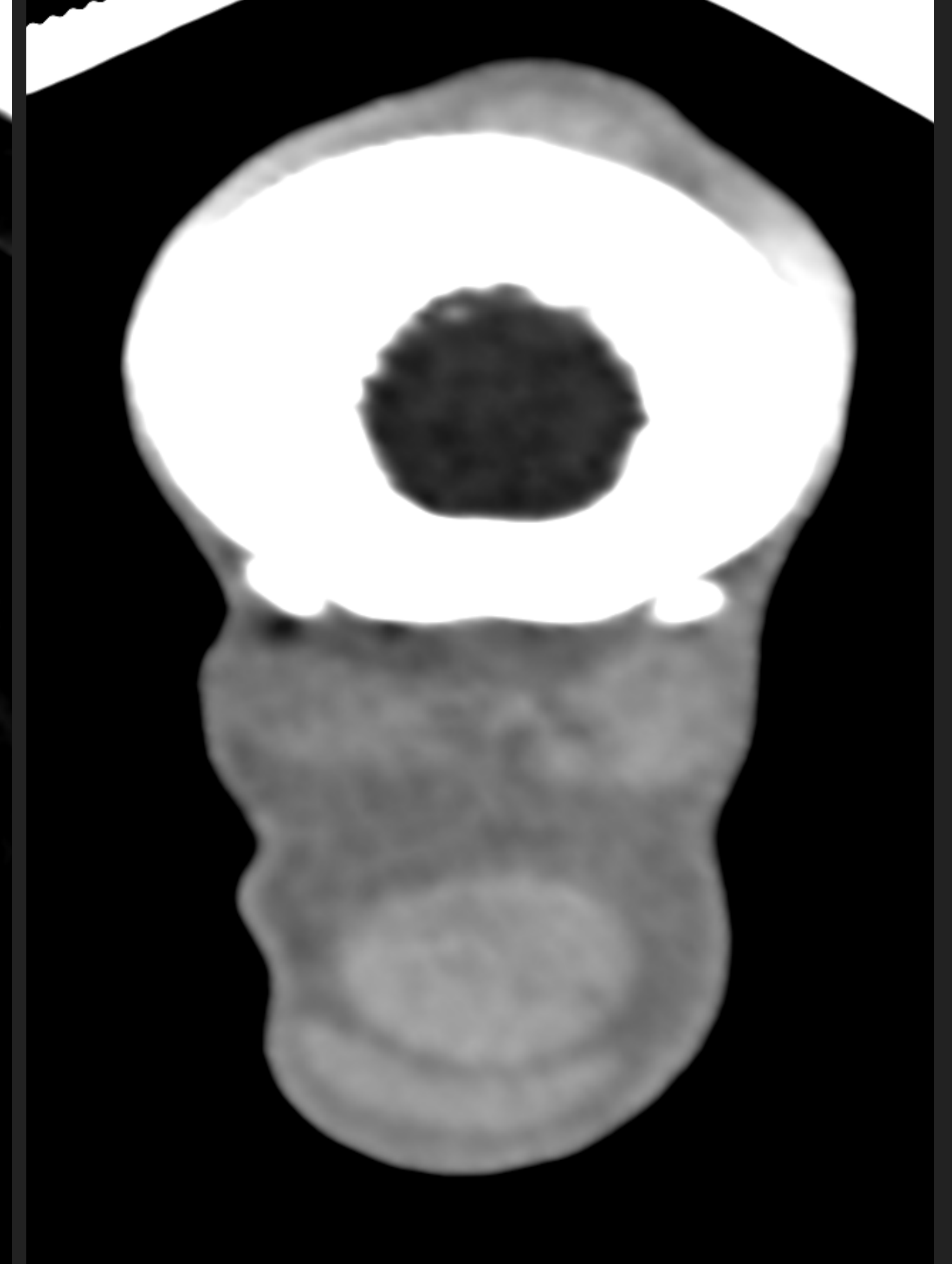
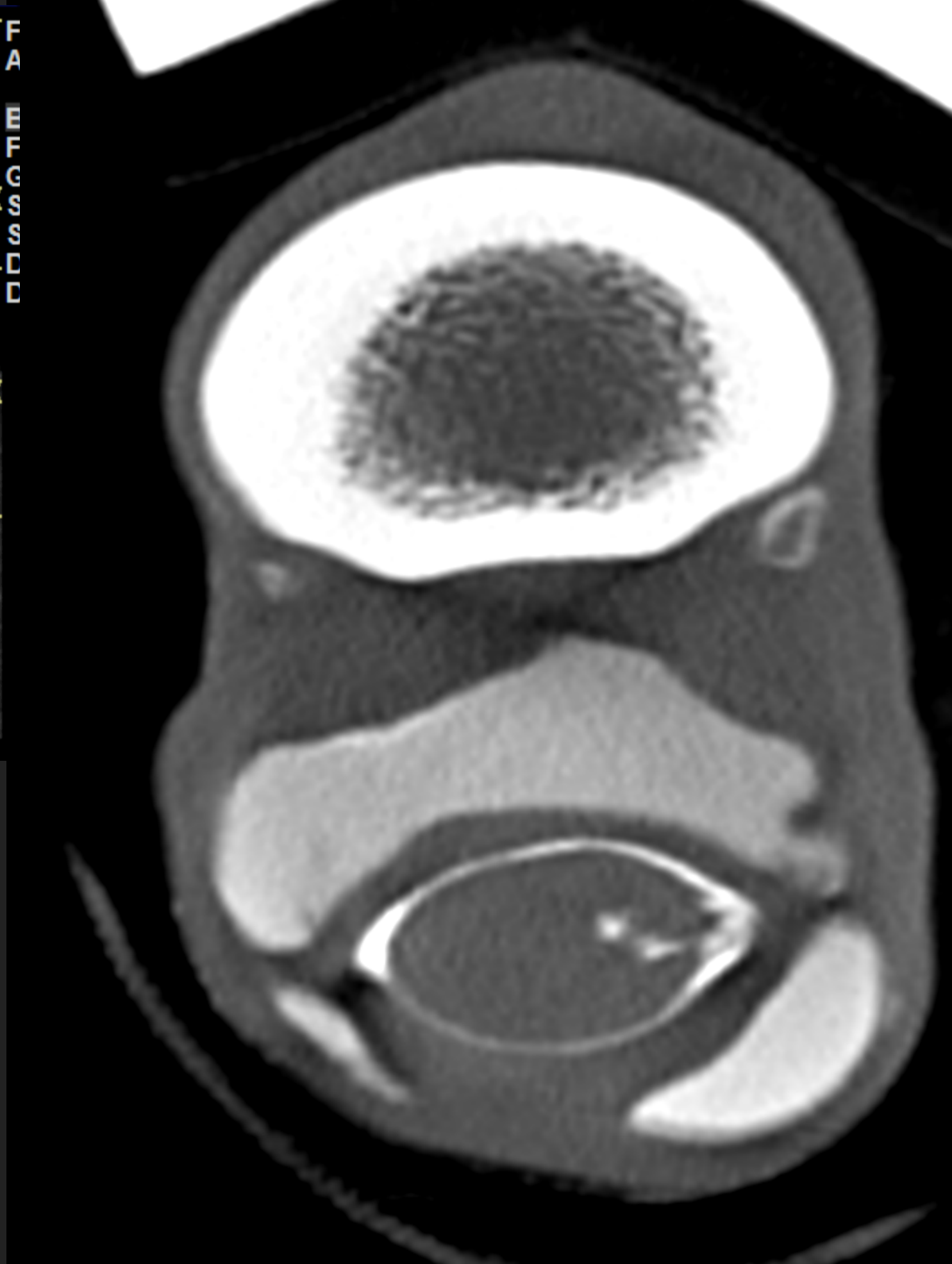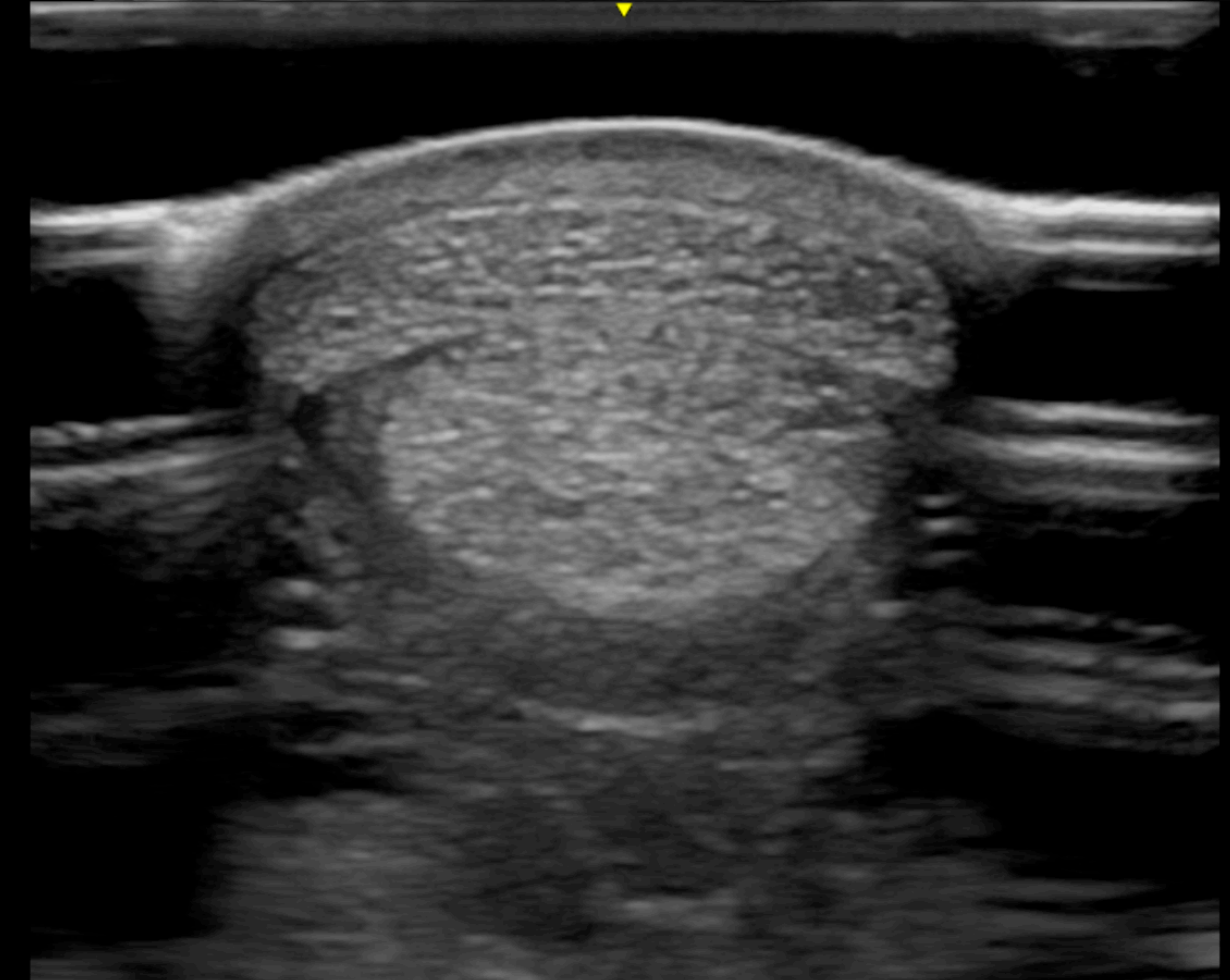
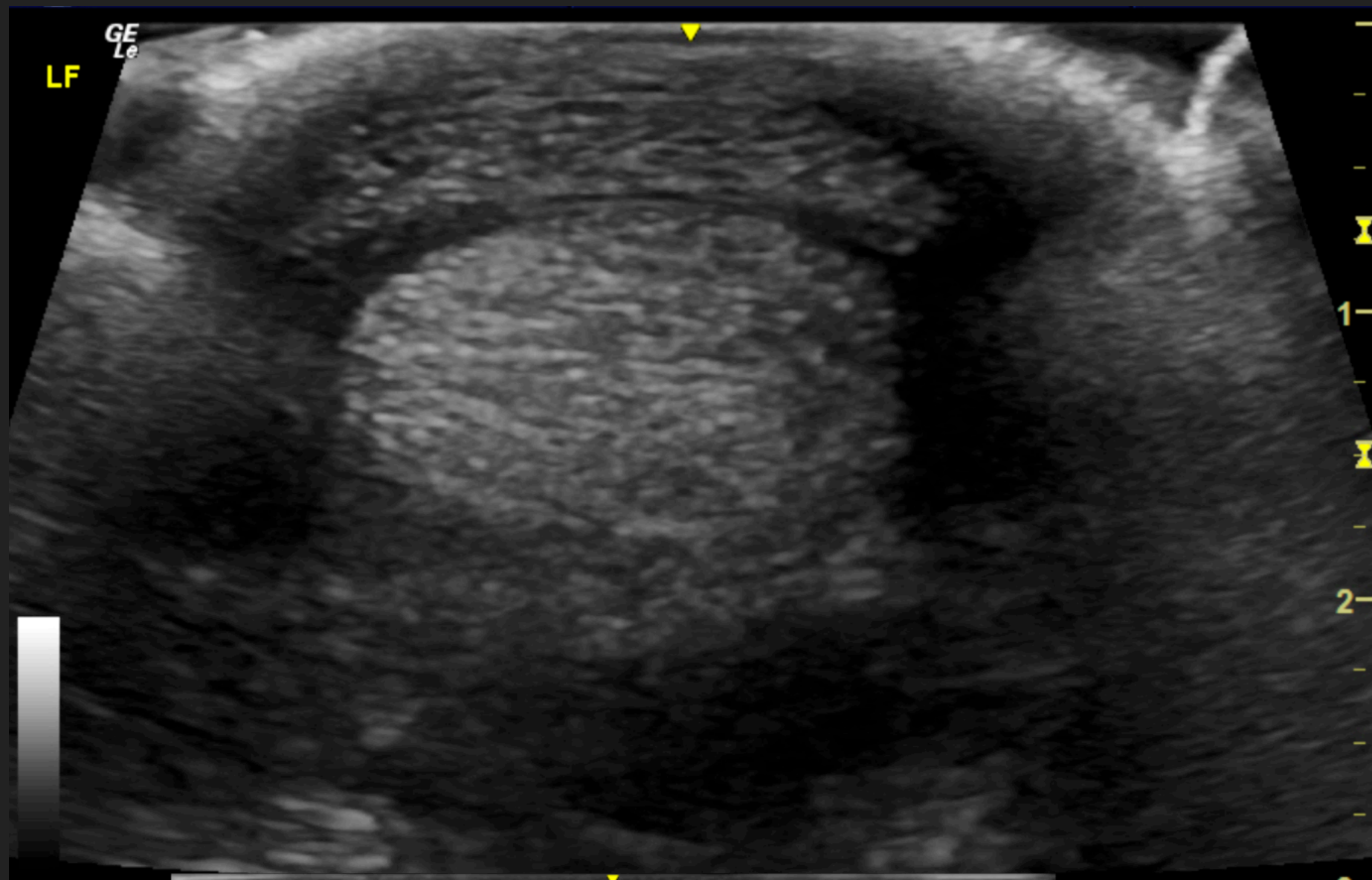
- ▶ Acute swelling in tendon sheath
- ▶ 2/5 LH Lameness



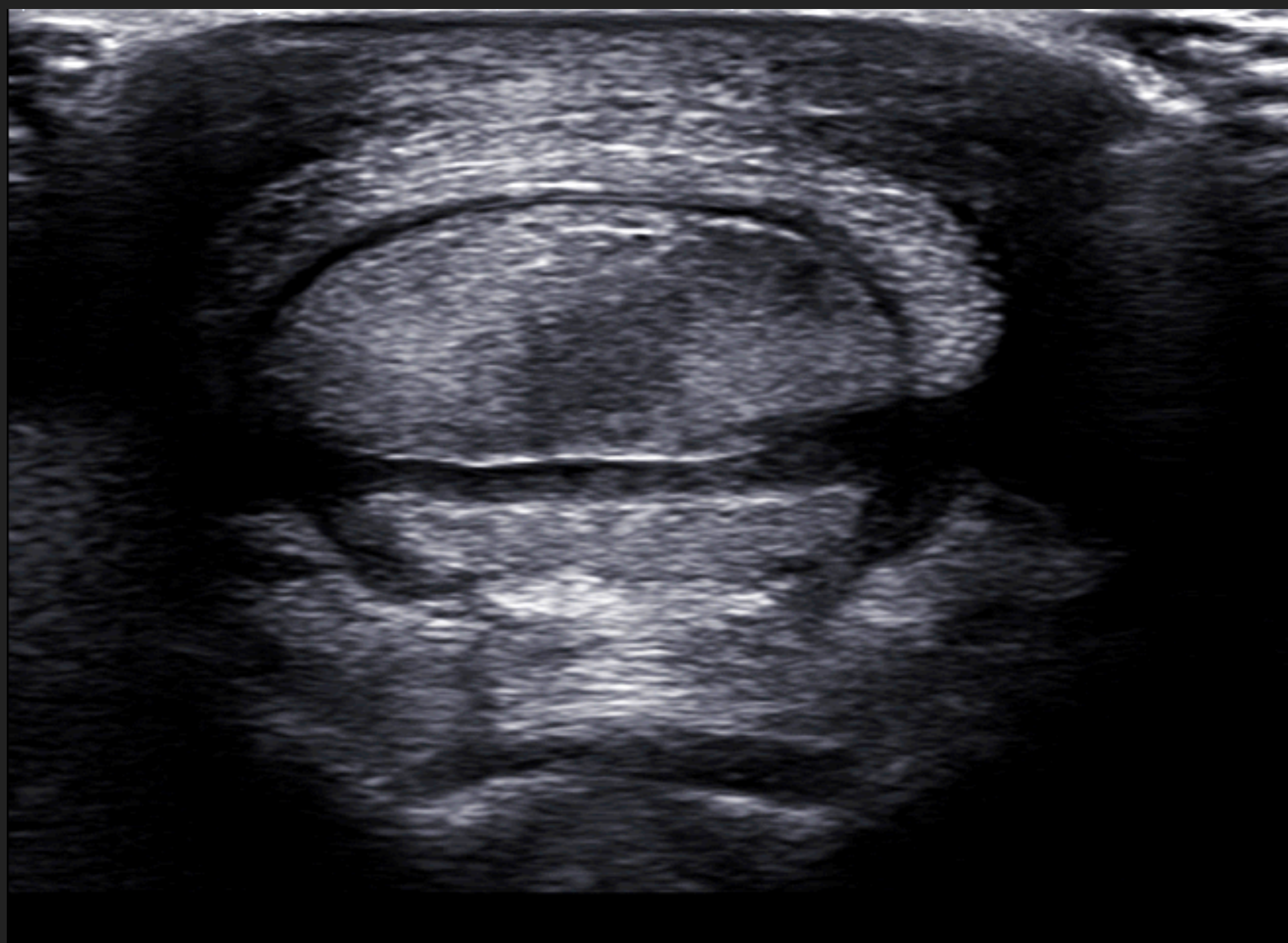
11 YO Dressage

2/5 LF Improves to Abx and sheath

DEEP DIGITAL FLEXOR TENDON + CONTRAST

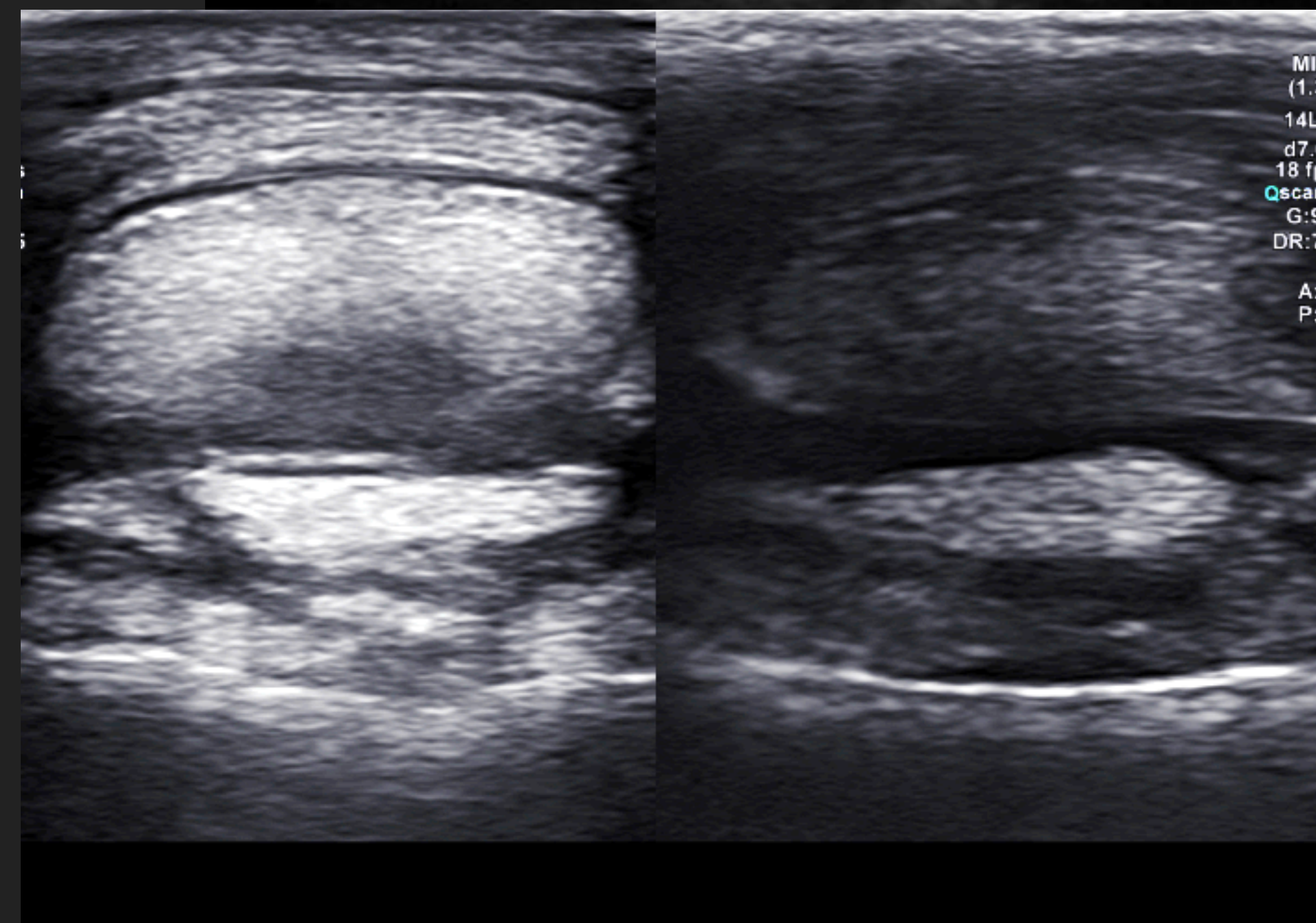
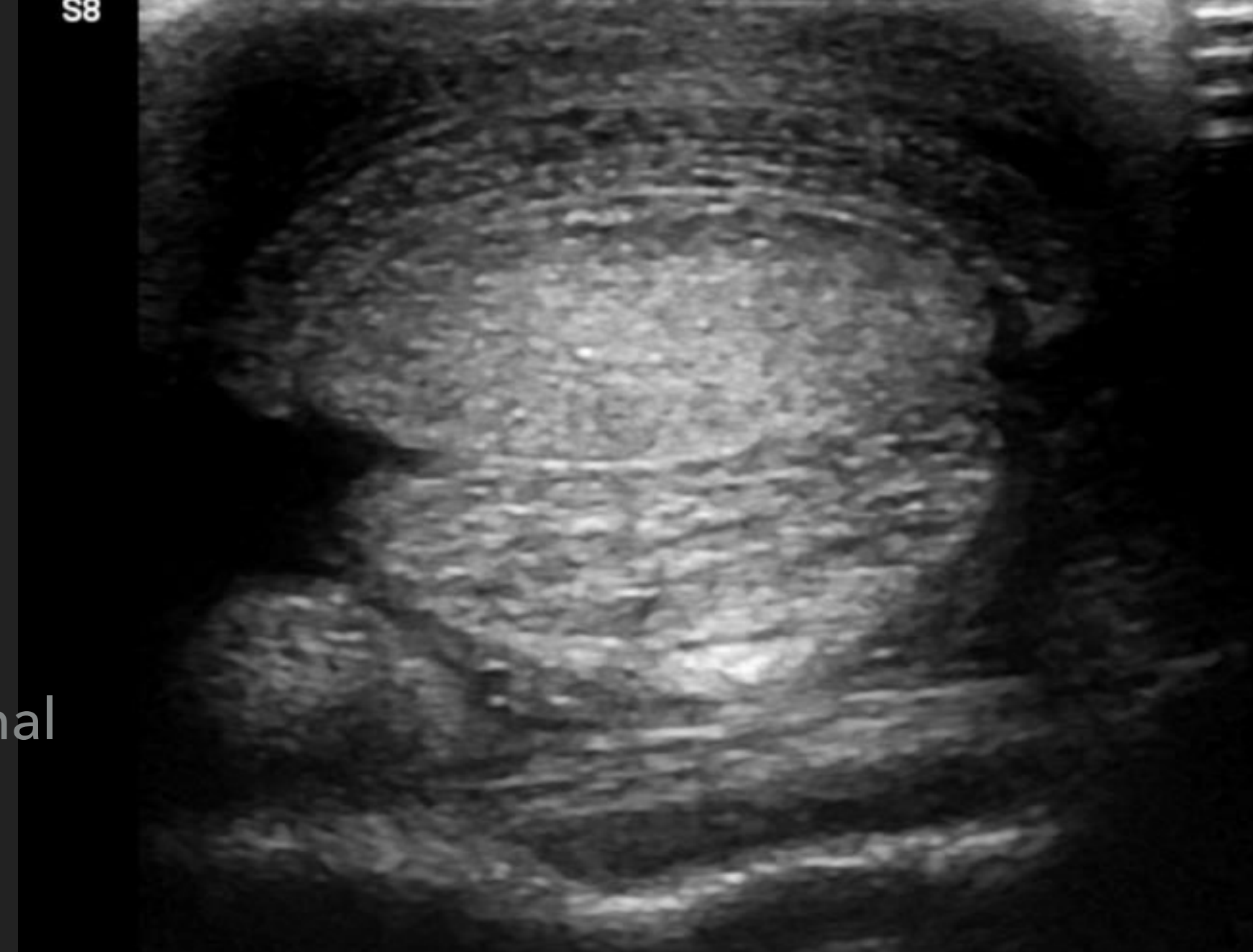


FLEXOR TENDONS



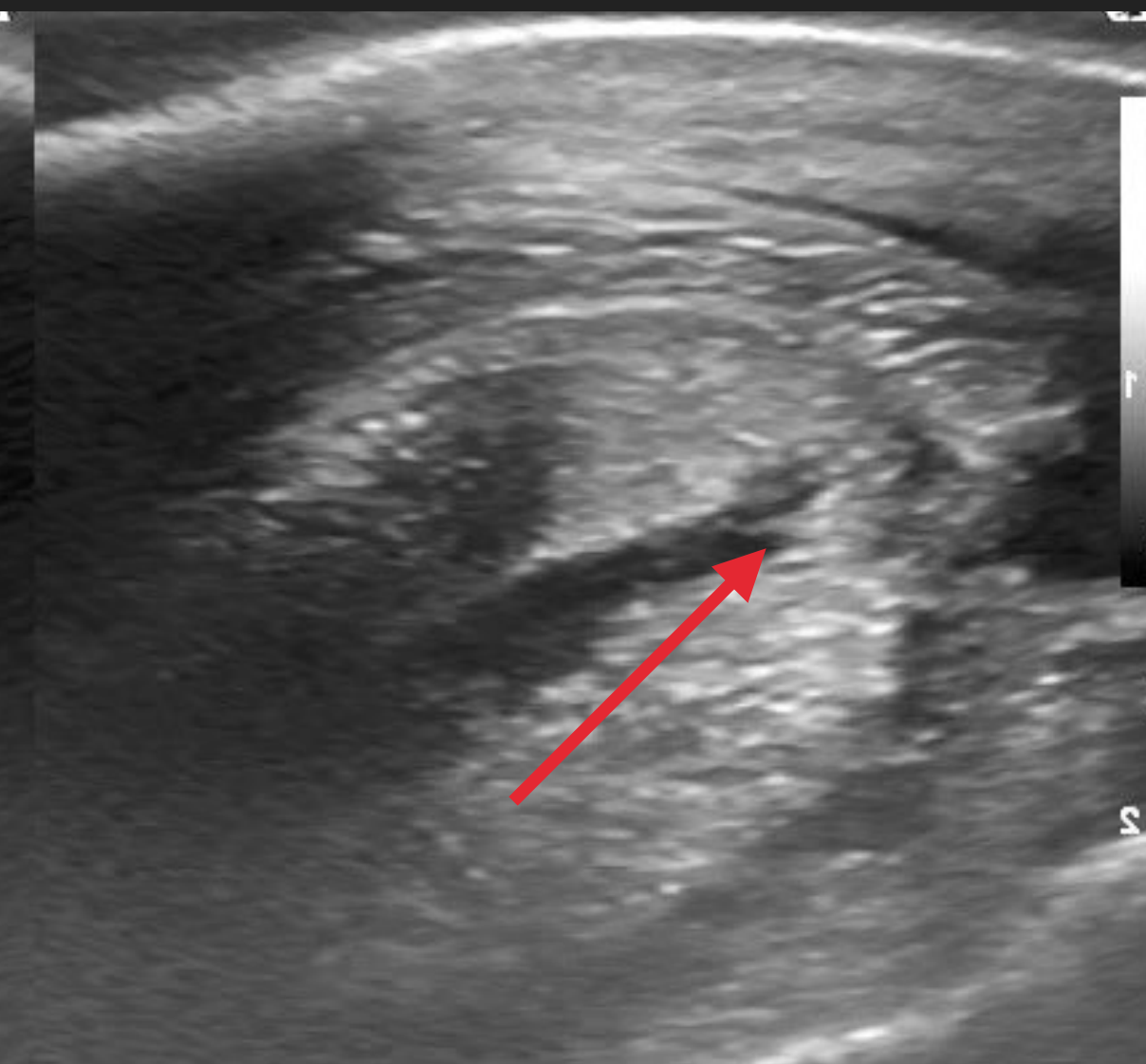
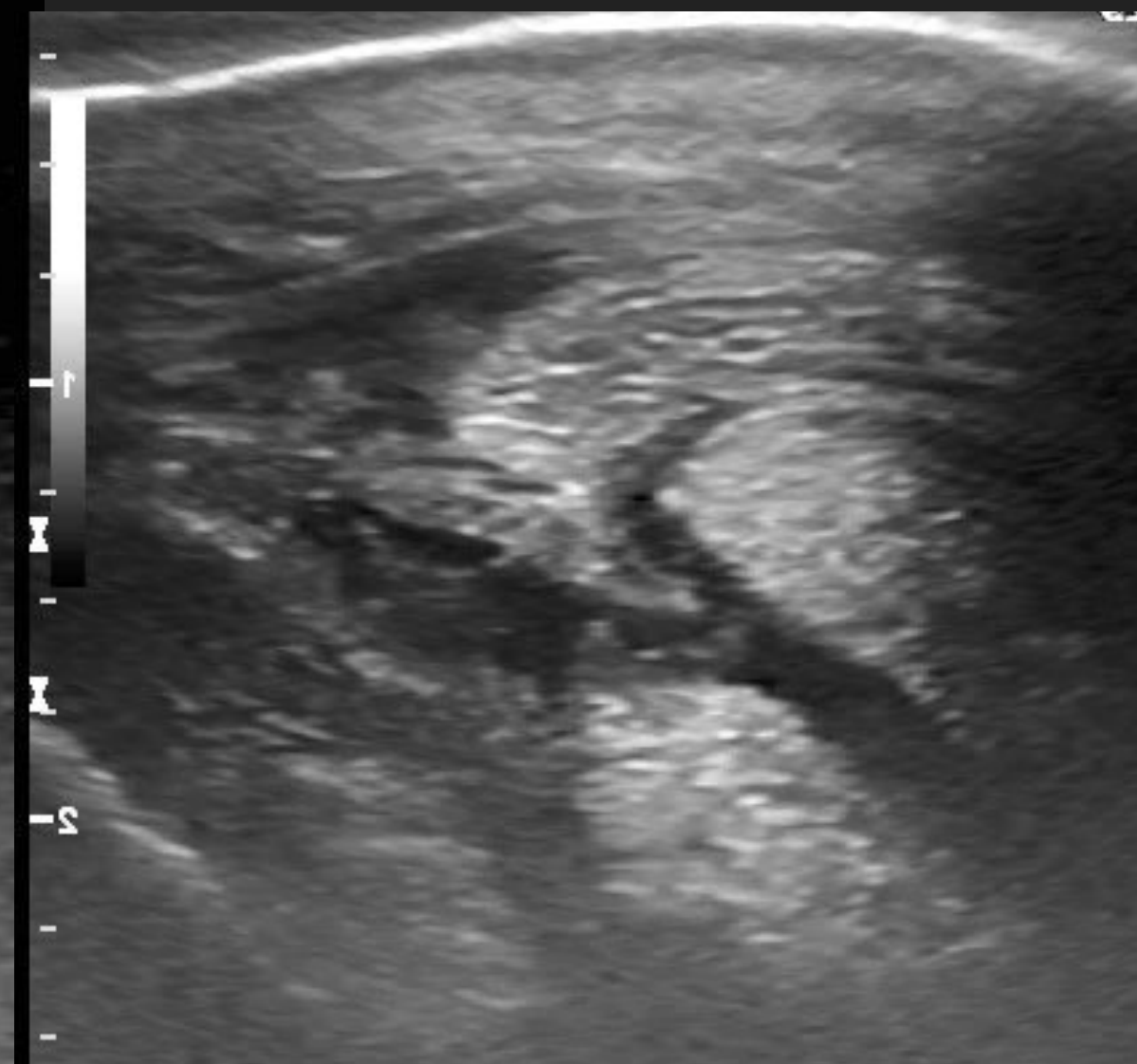
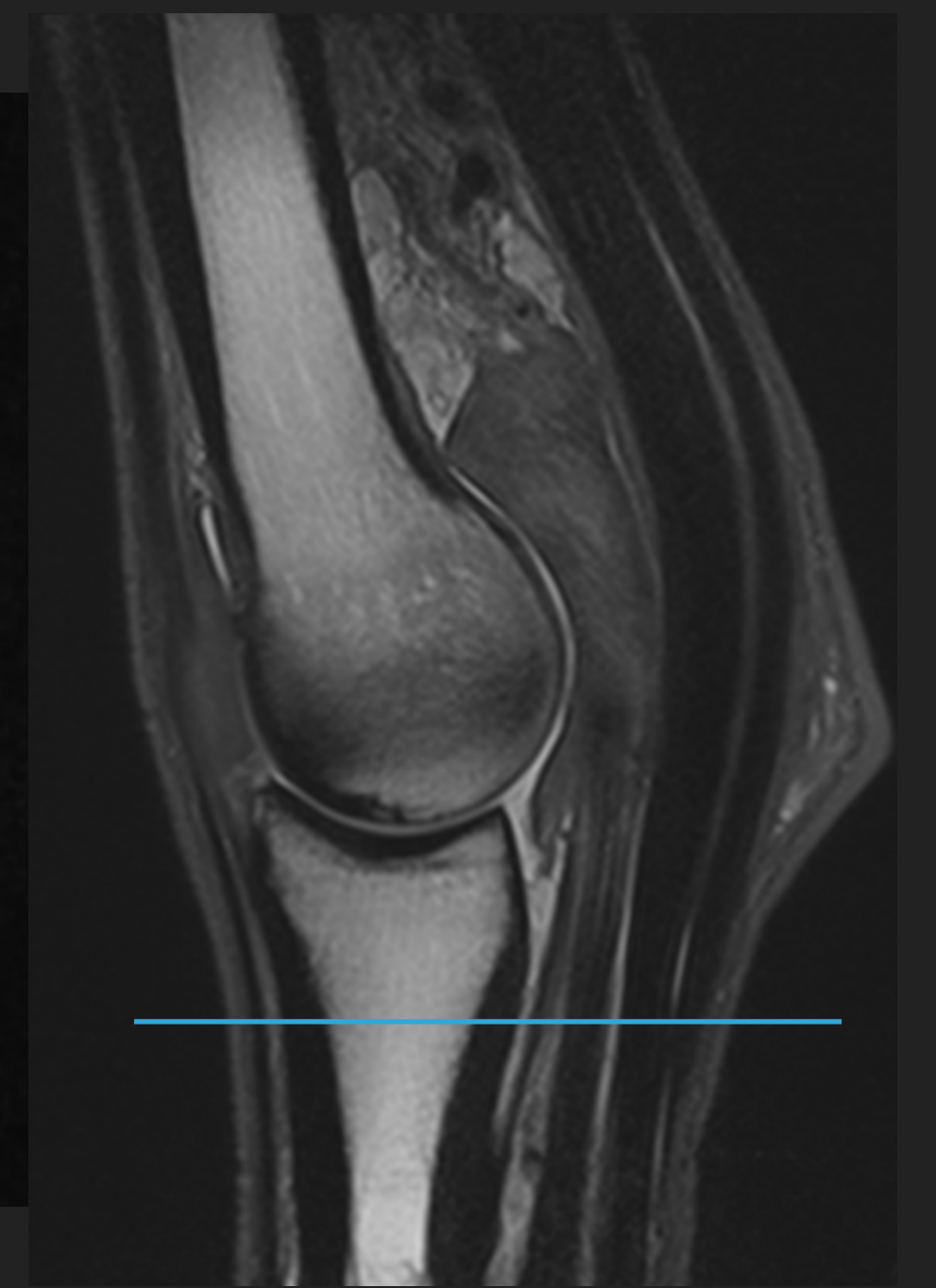
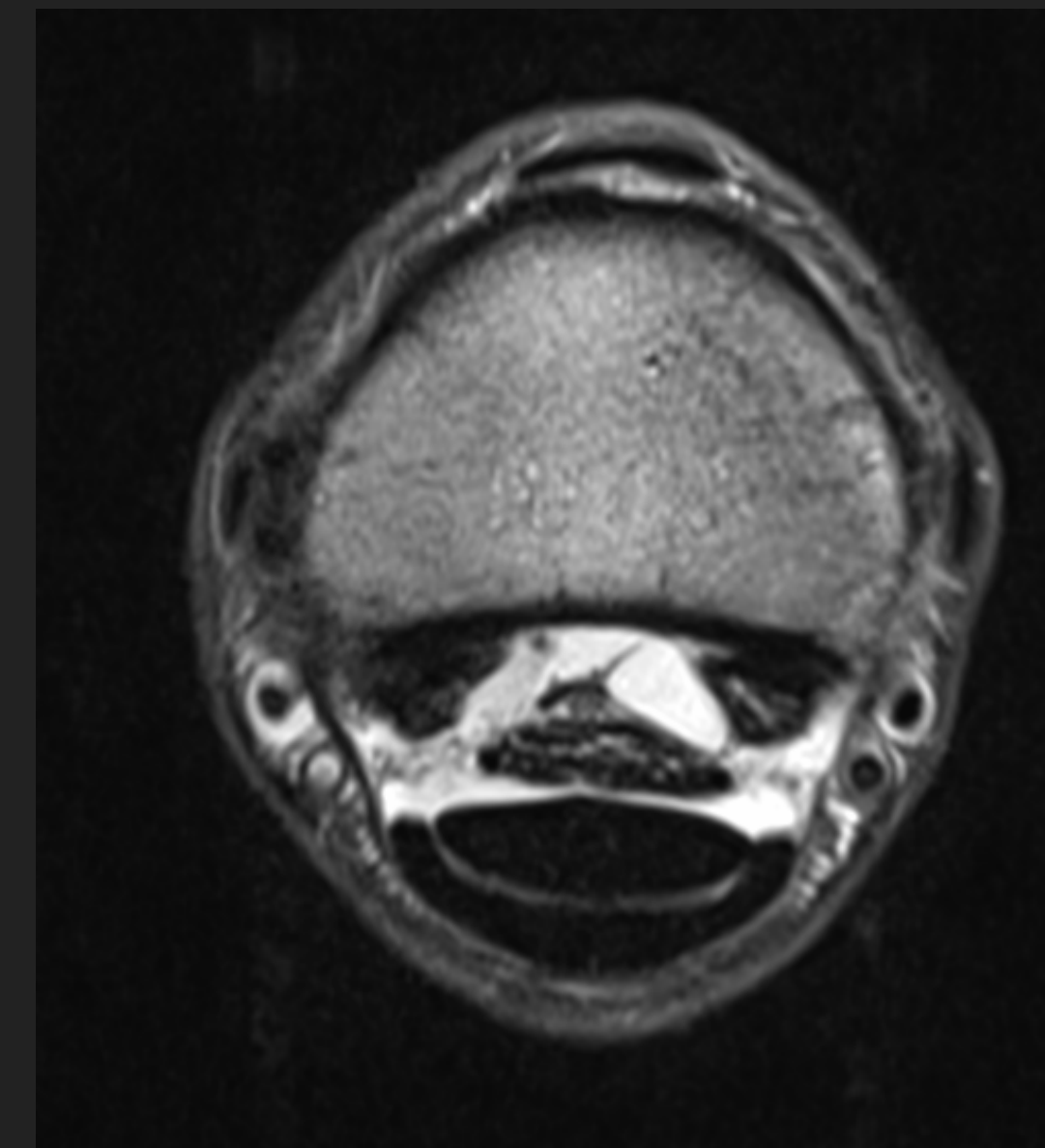
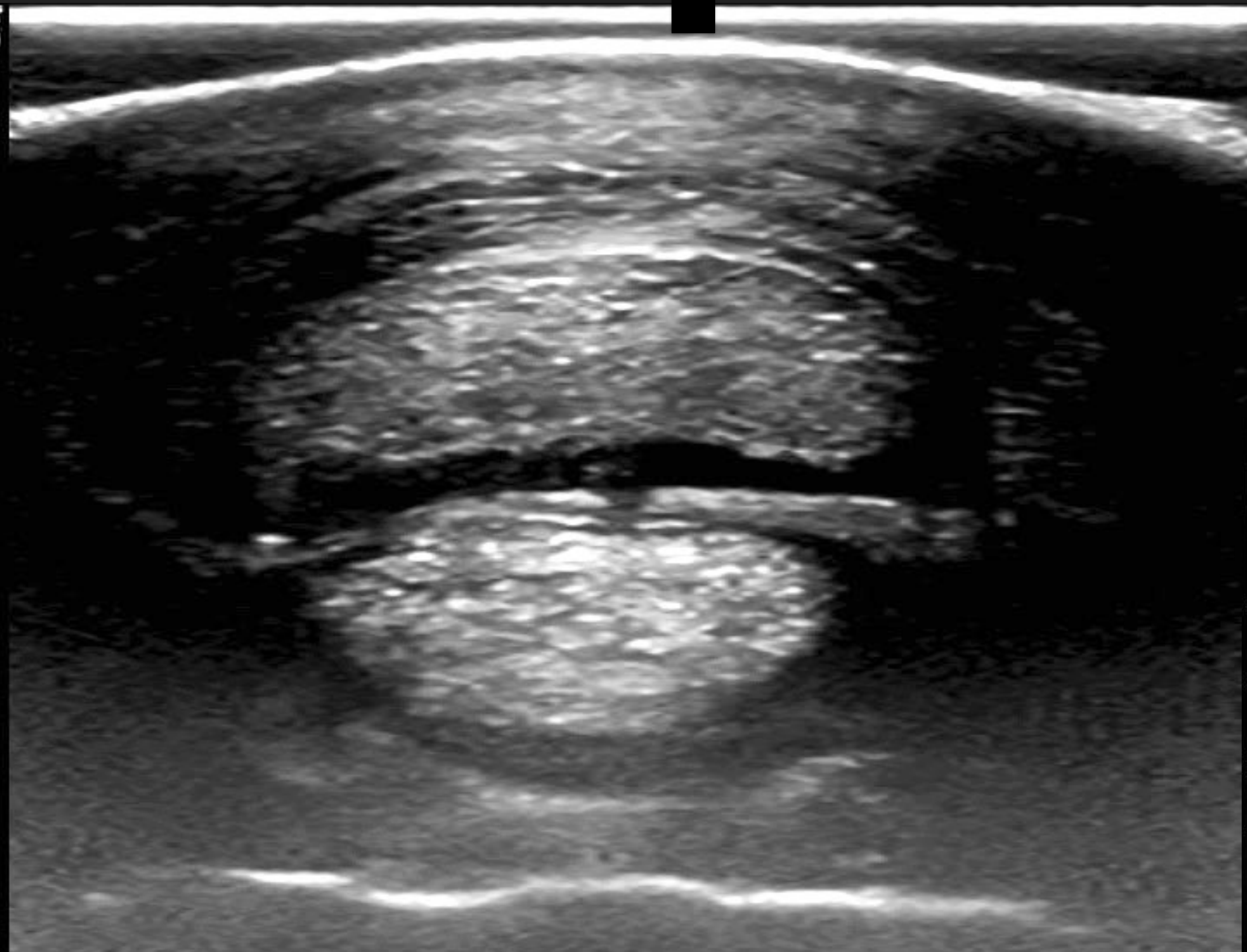
8 YO QH x Ranch horse

Normal

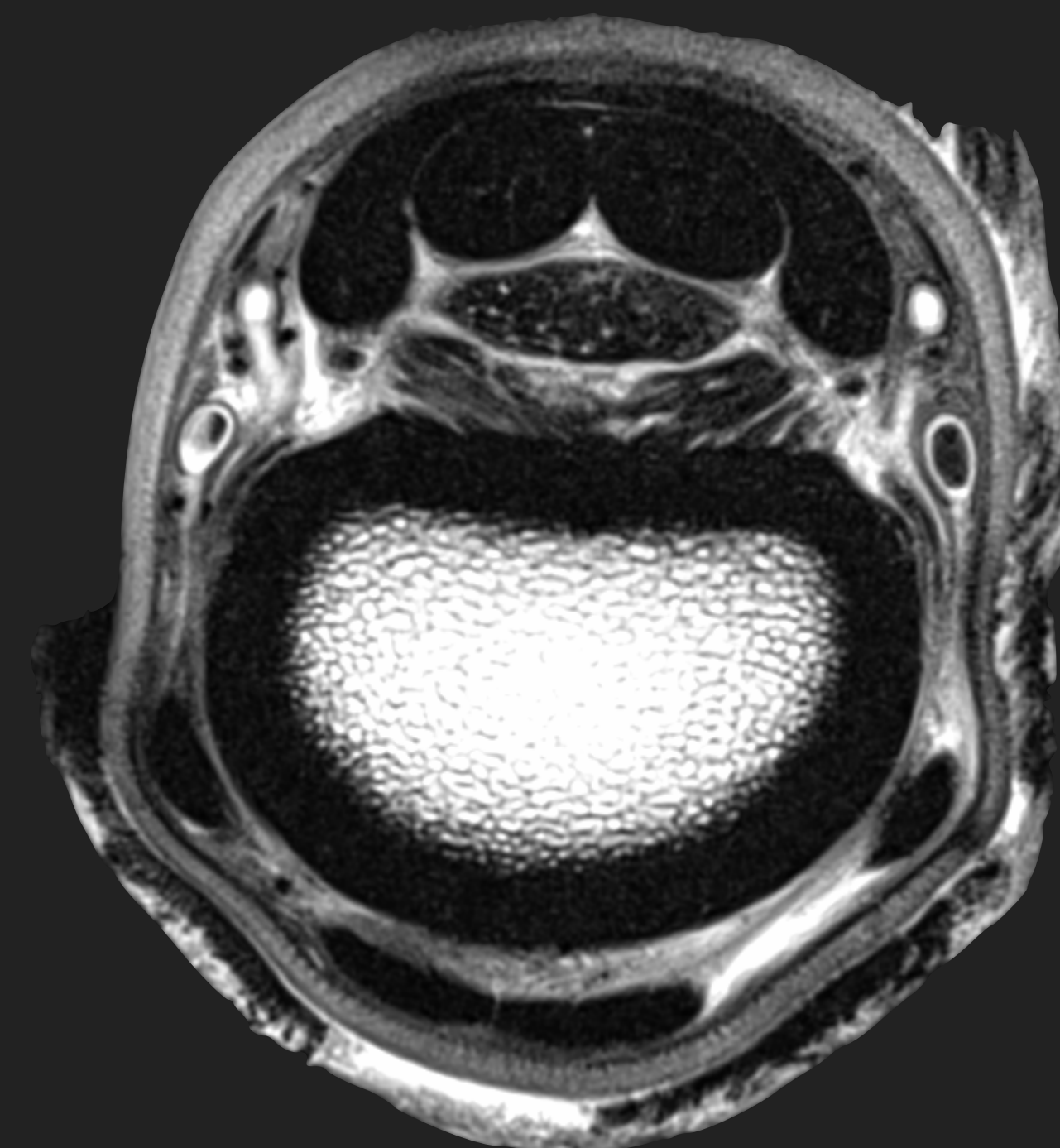
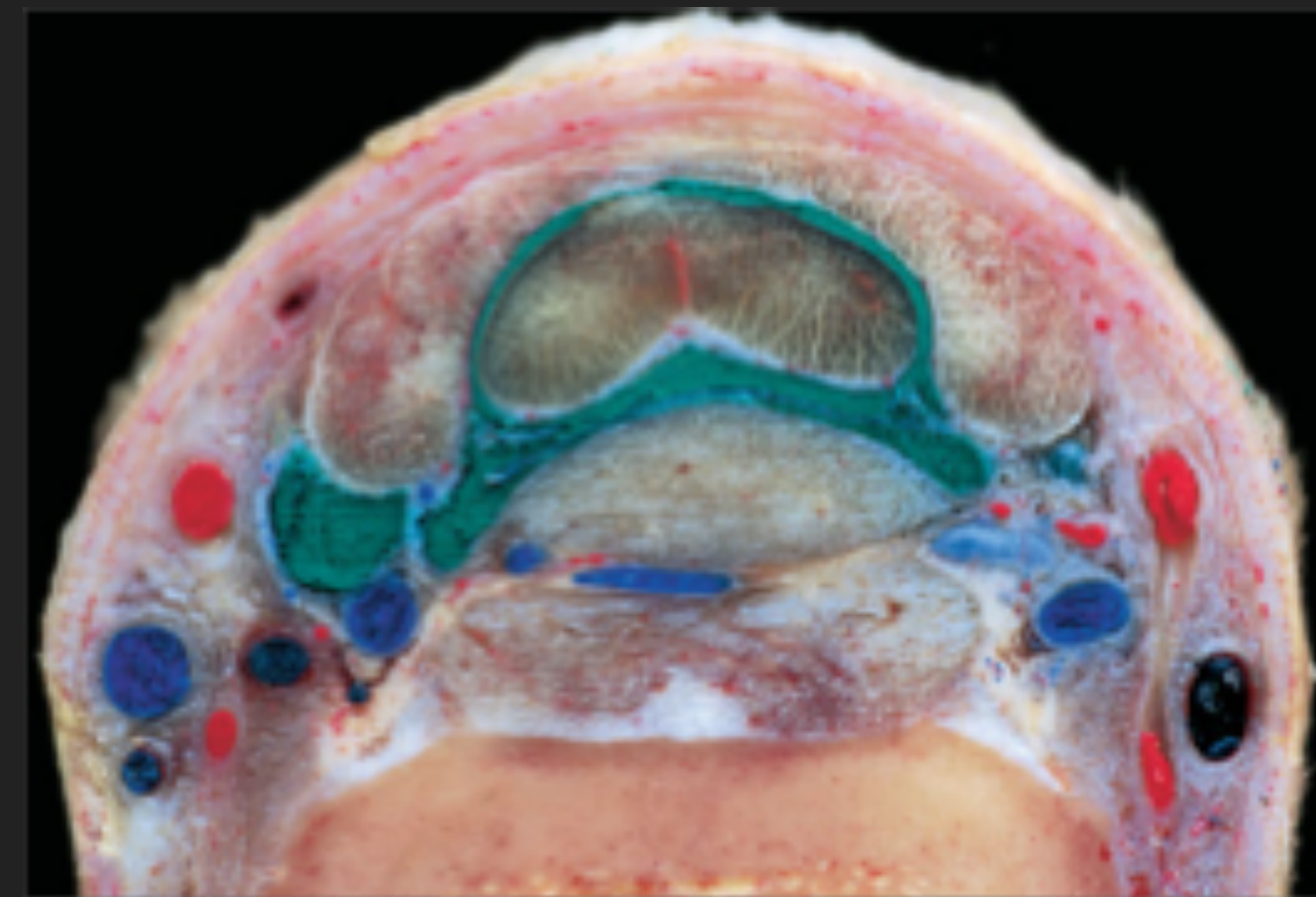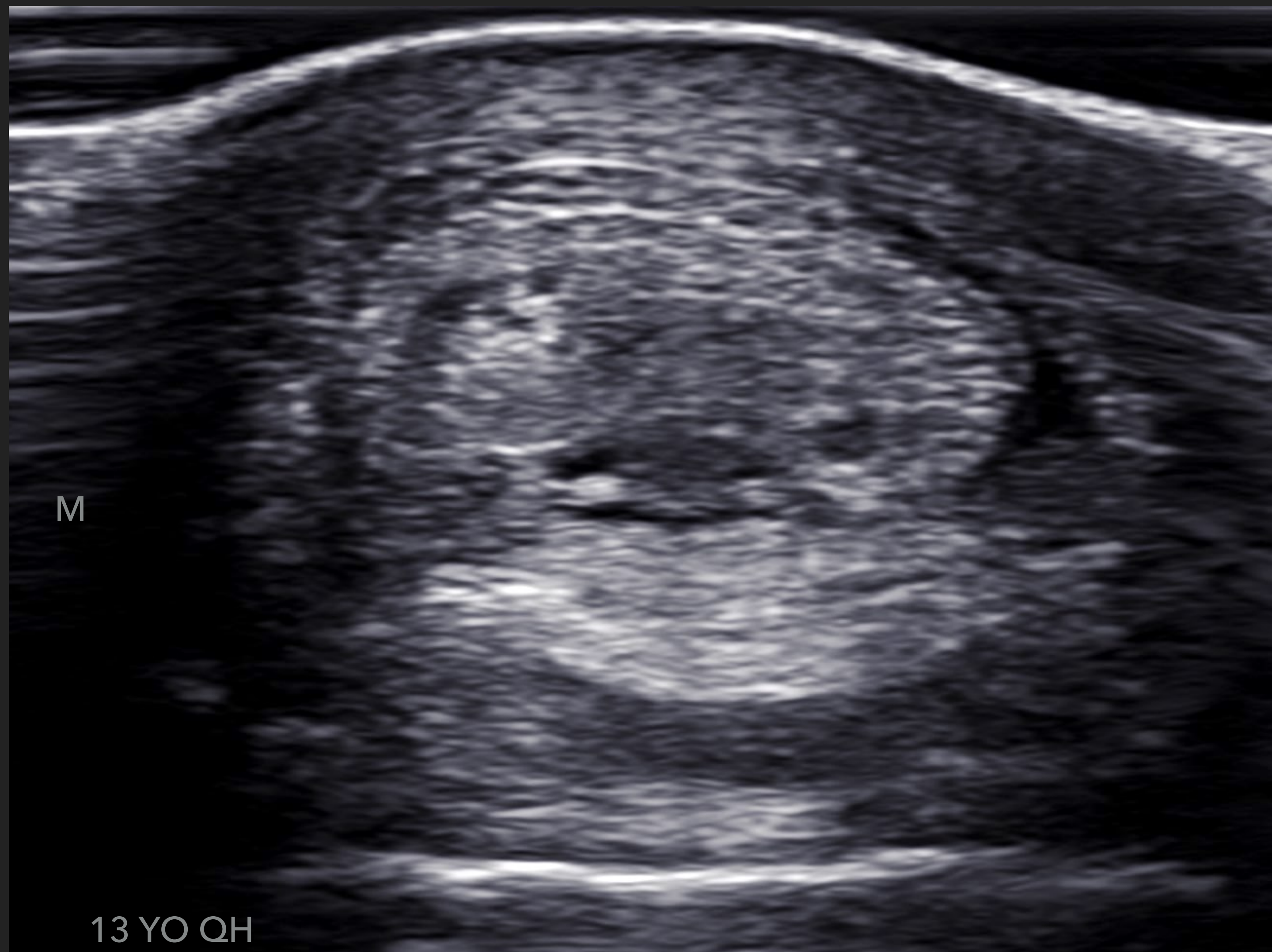


MIm
(1.3)
14L5
d7.0
18 fps
Qscan
G:90
DR:75
A:2
P:3

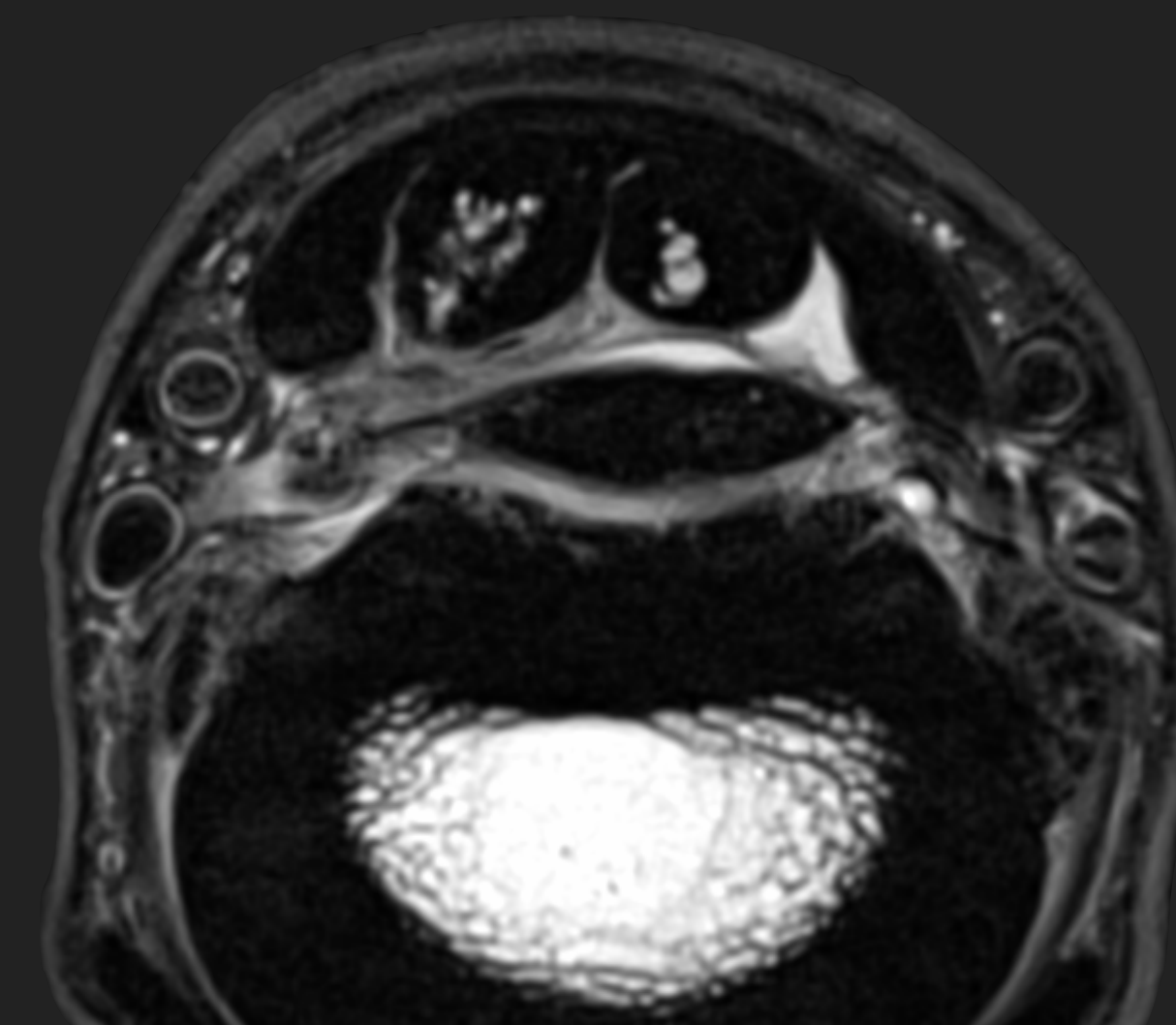
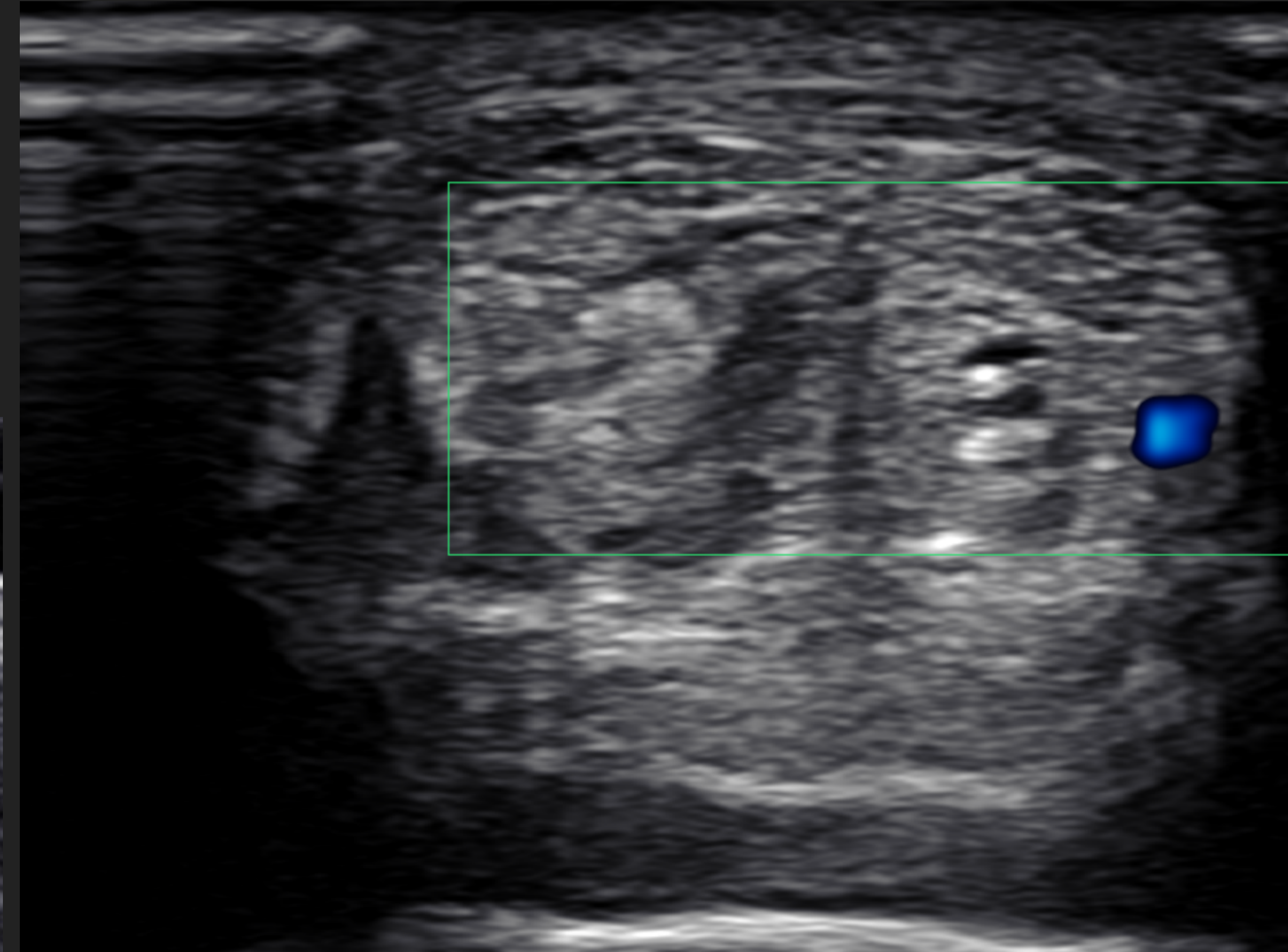
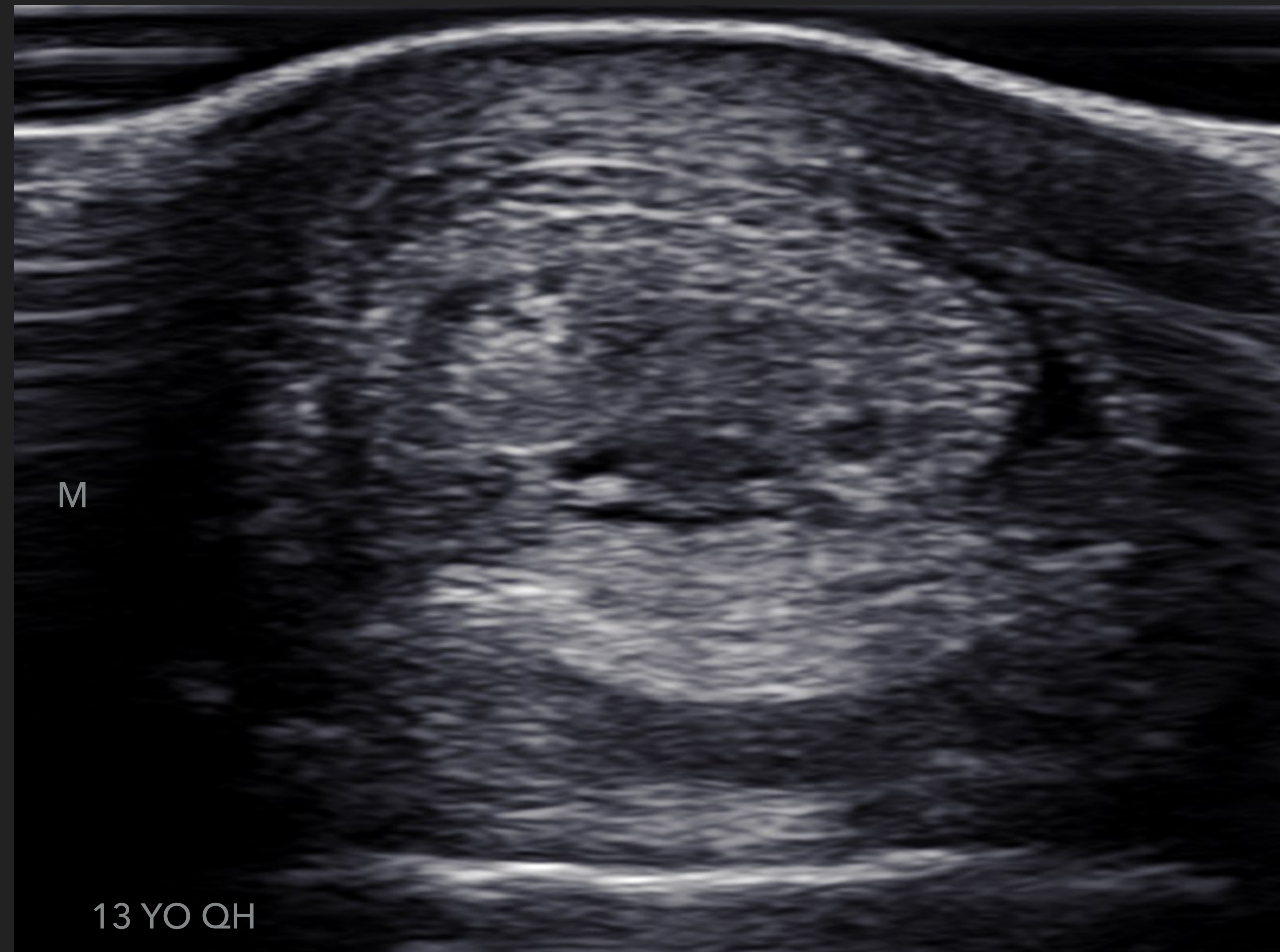
FLEXOR TENDONS: DDF



FLEXOR TENDONS



FLEXOR TENDONS



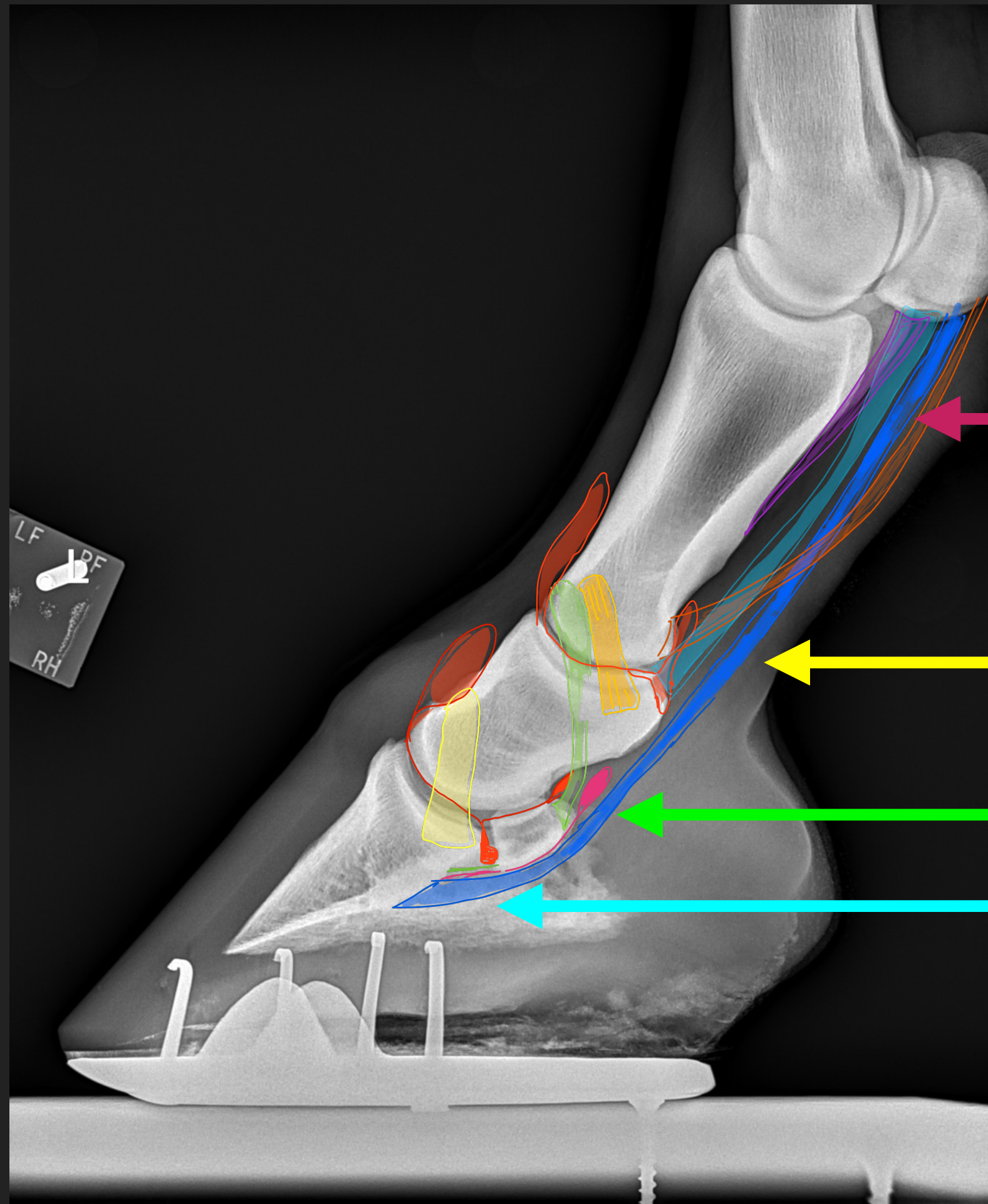
Magnetic resonance imaging evaluation of 264 horses with foot pain: The podotrochlear apparatus, deep digital flexor tendon and collateral ligaments of the distal interphalangeal joint

S. DYSON* and R. MURRAY

Deep digital flexor tendon lesions in the pastern are associated with the presence of distal tendinopathy

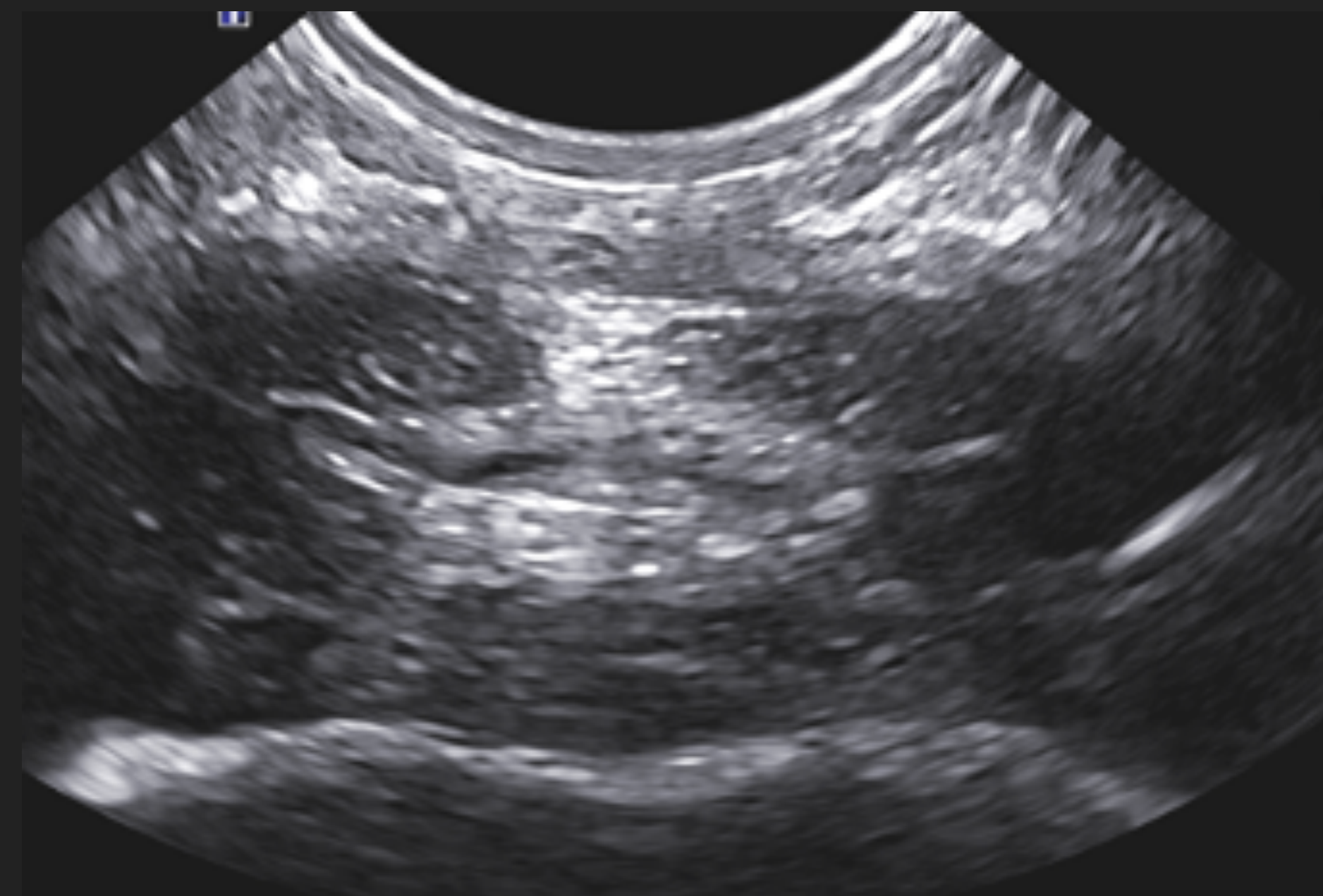
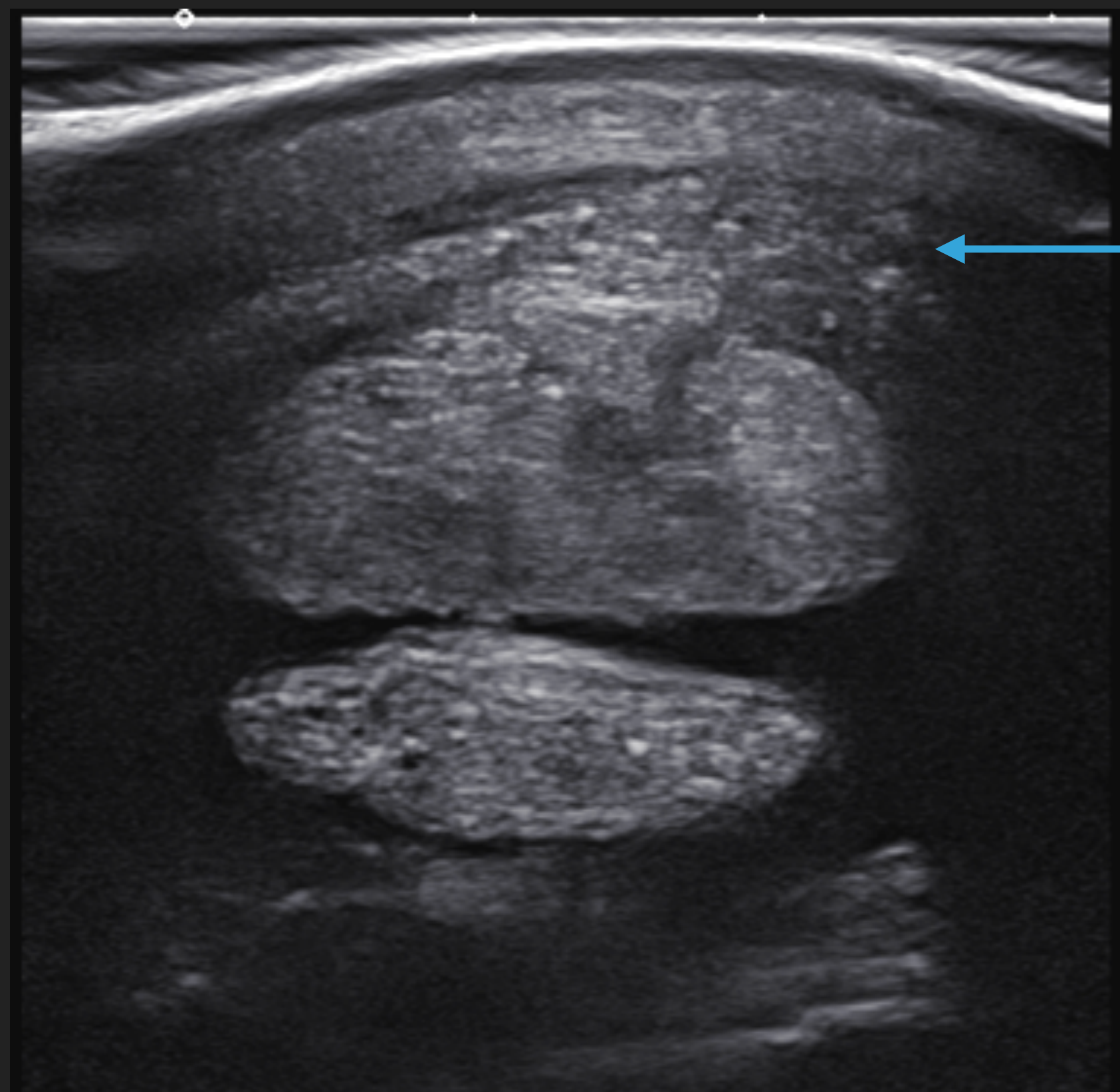
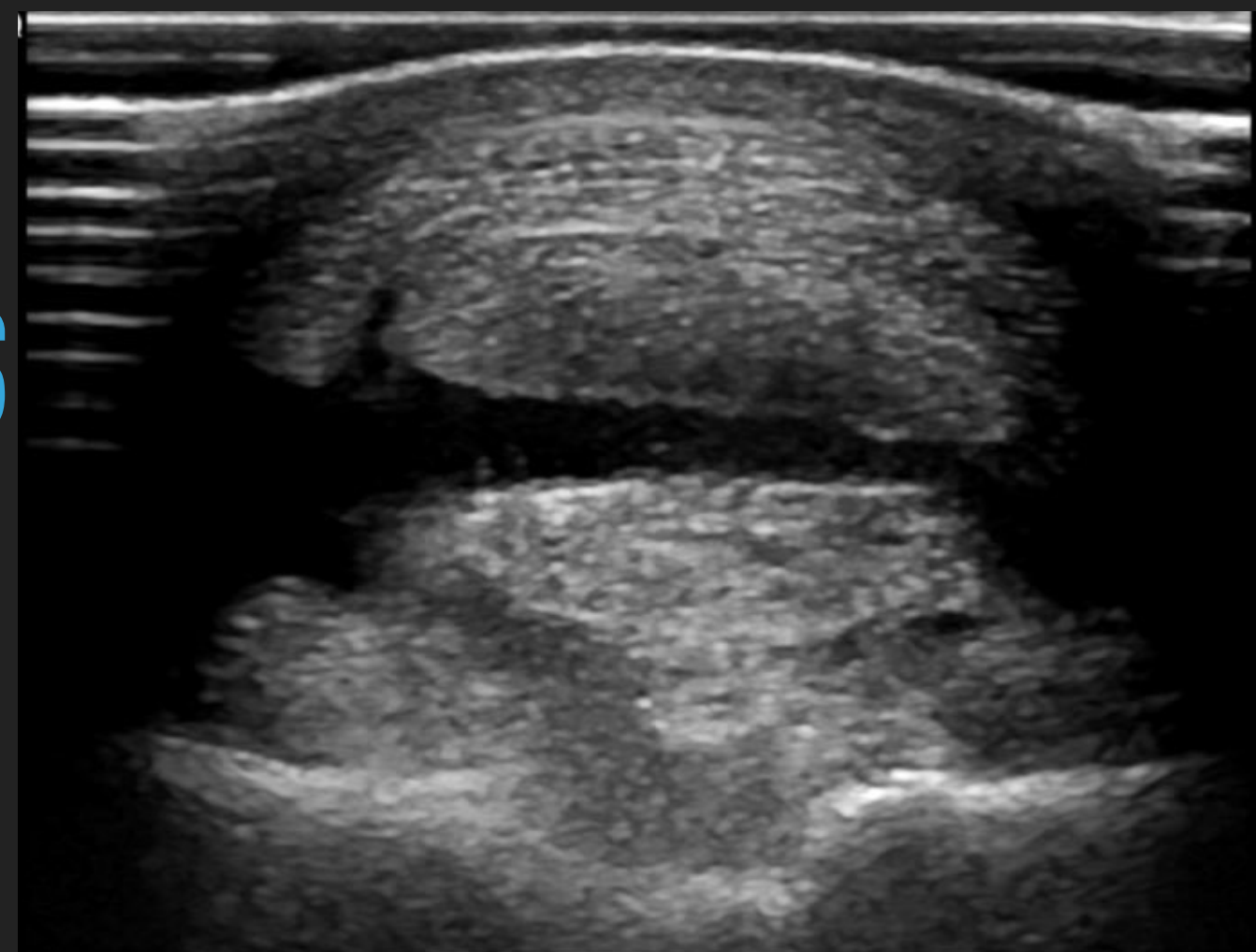
Elizabeth V. Acutt  | Erin K. Contino  | David D. Frisbie  | Myra F. Barrett 

DEEP DIGITAL FLEXOR TENDON

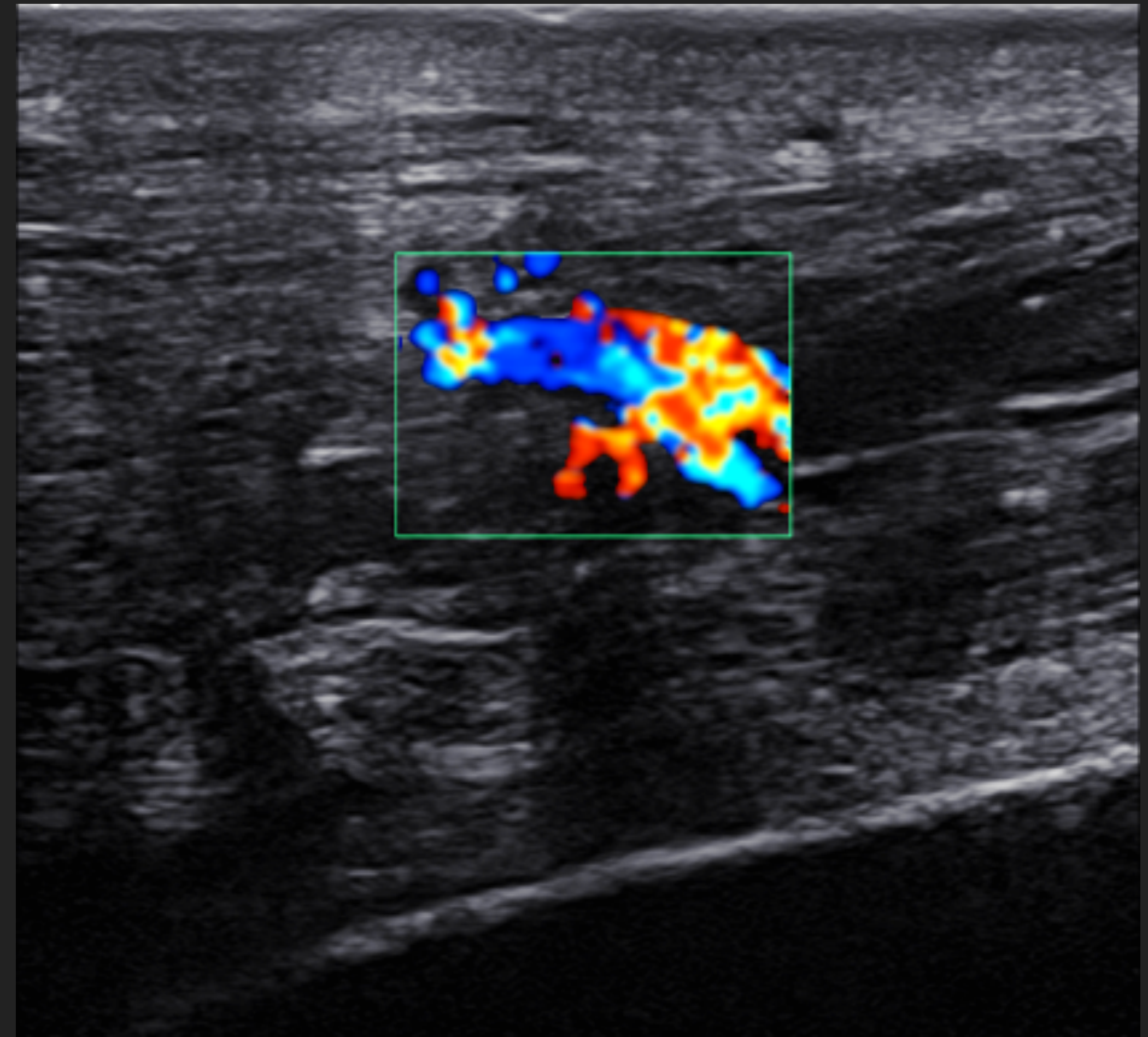
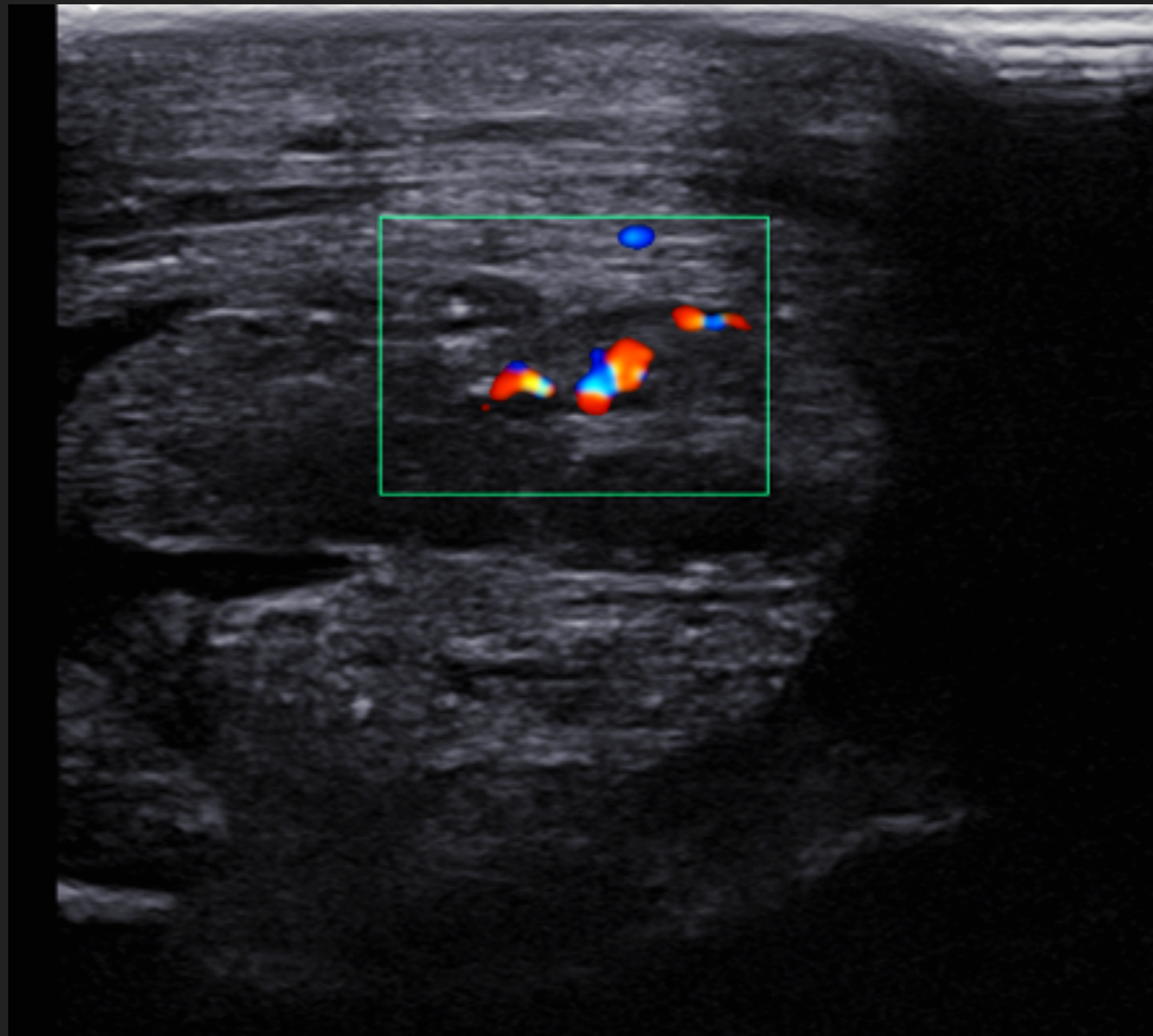


- 4 Dorsolateral tears
 - 3 deep digital flexor tendon tear
 - 1
 - 2
- 75-97% chance lesion here

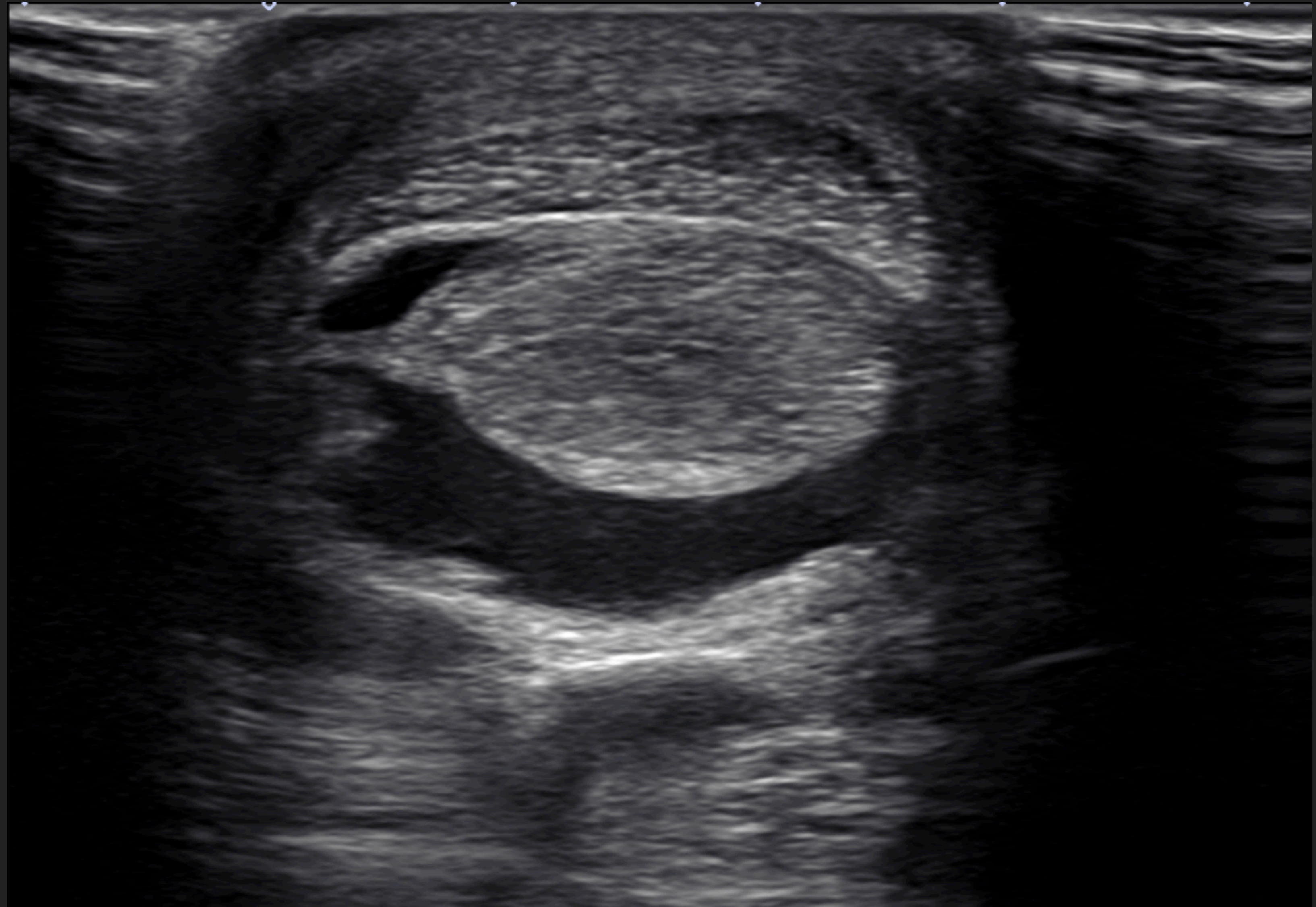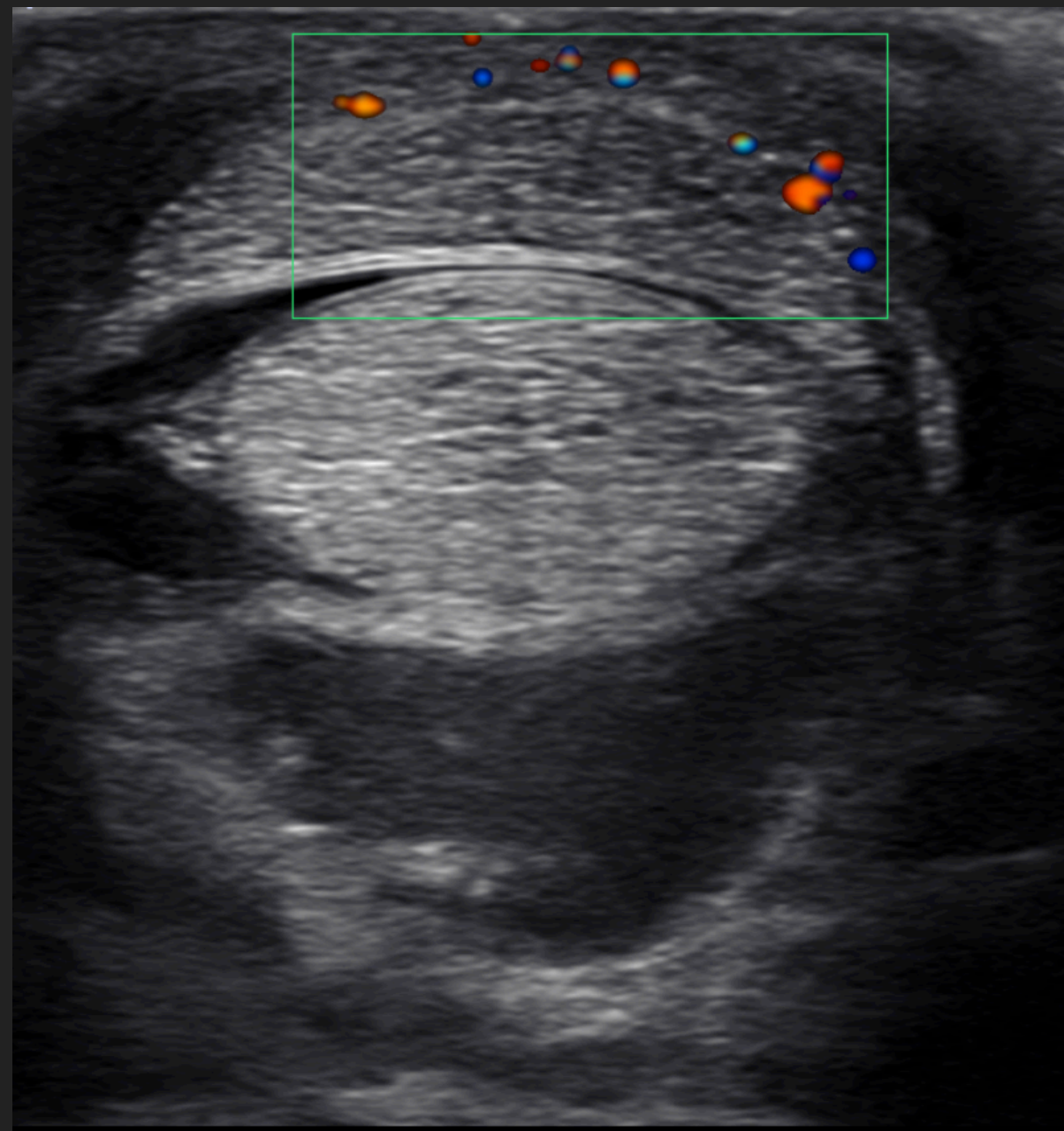
FLEXOR TENDONS



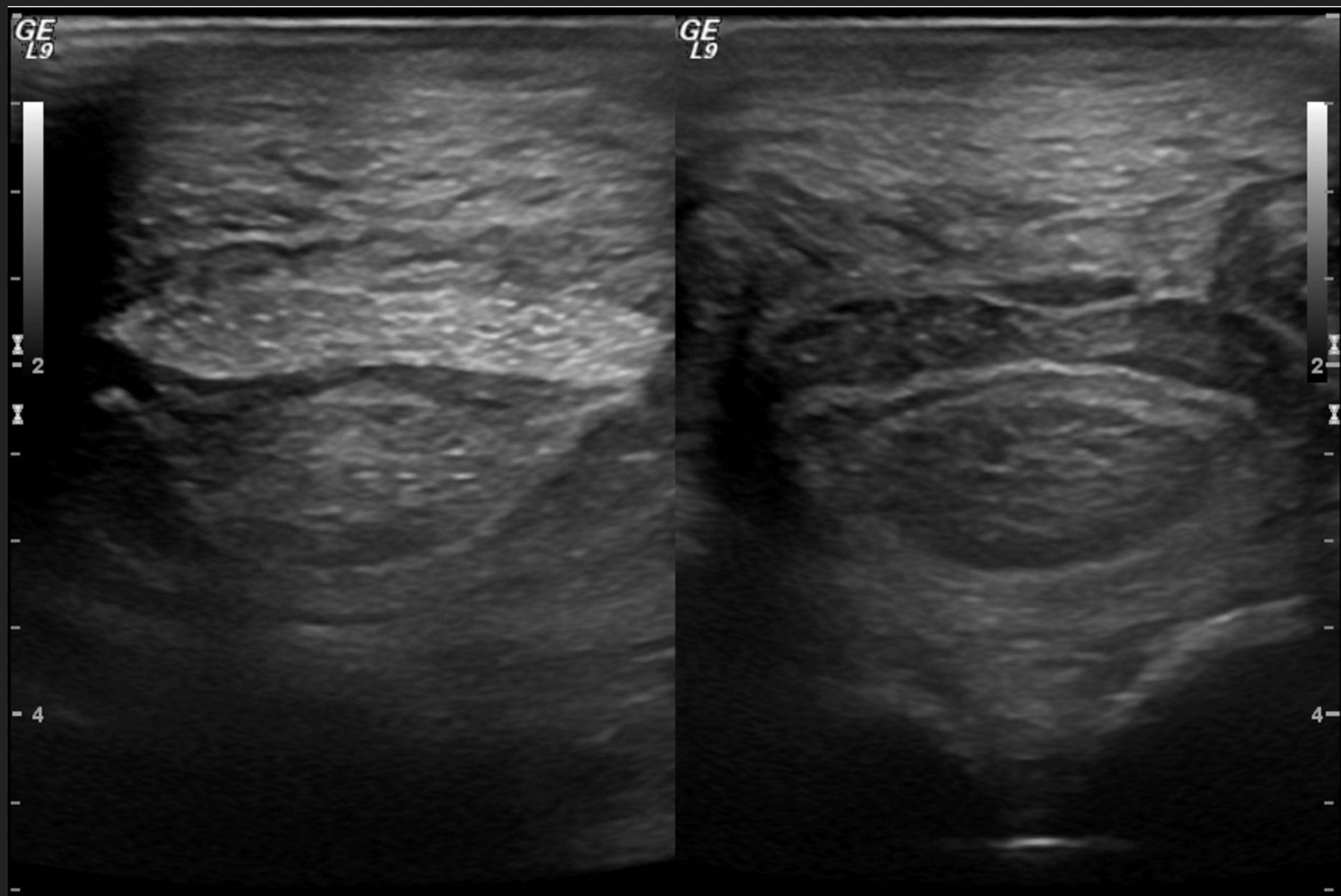
FLEXOR TENDONS



FLEXOR TENDONS

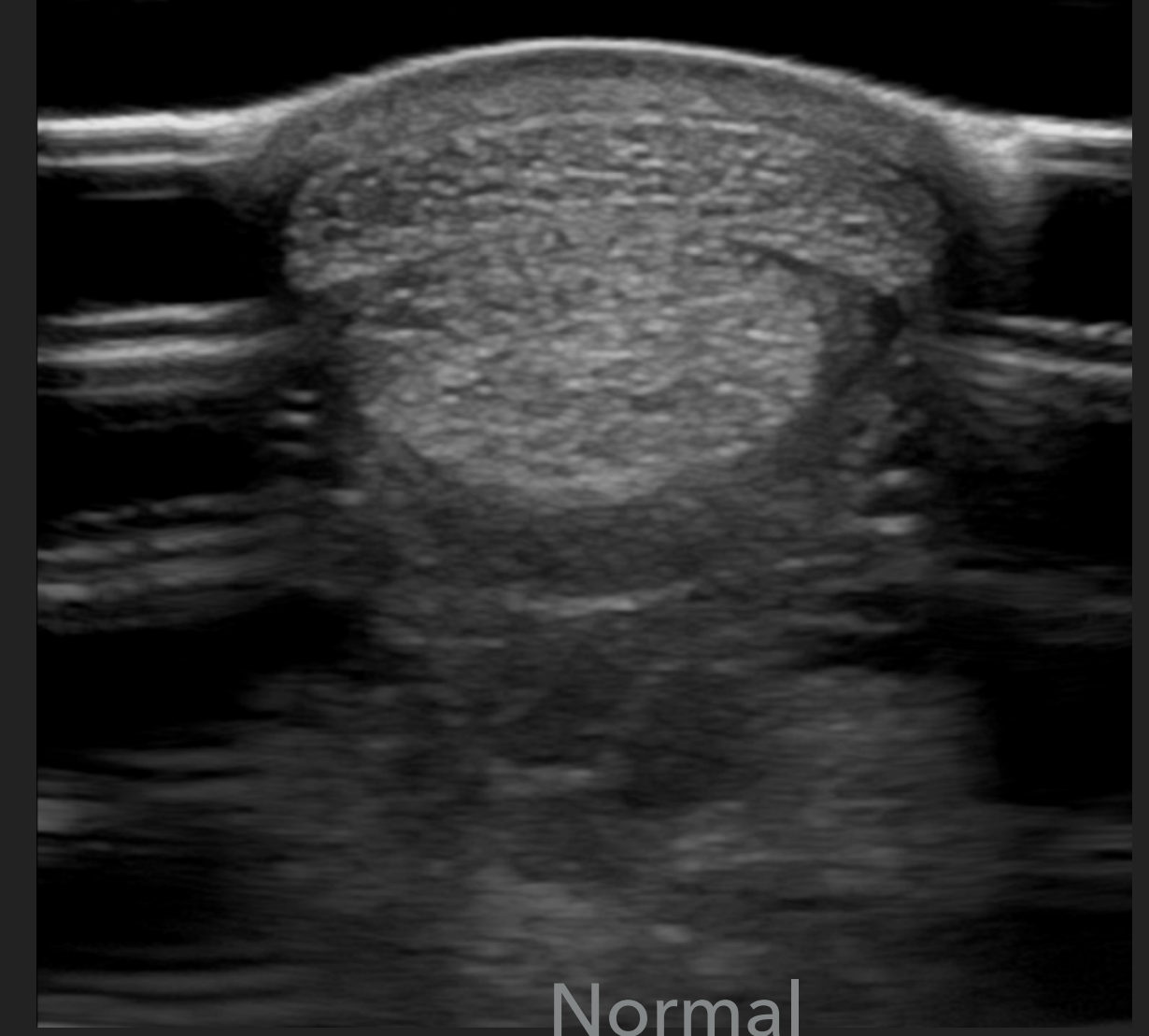


FLEXOR TENDONS

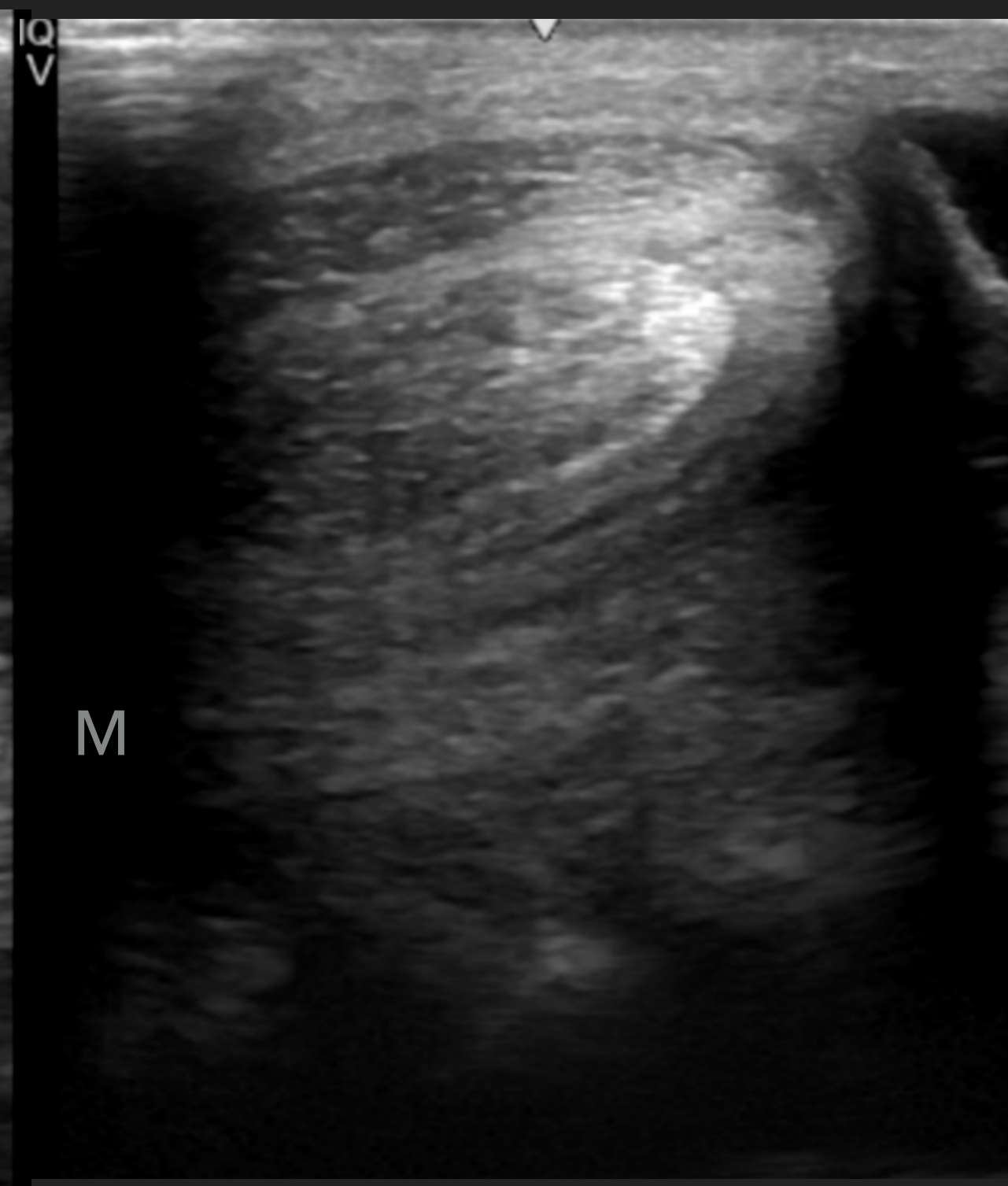
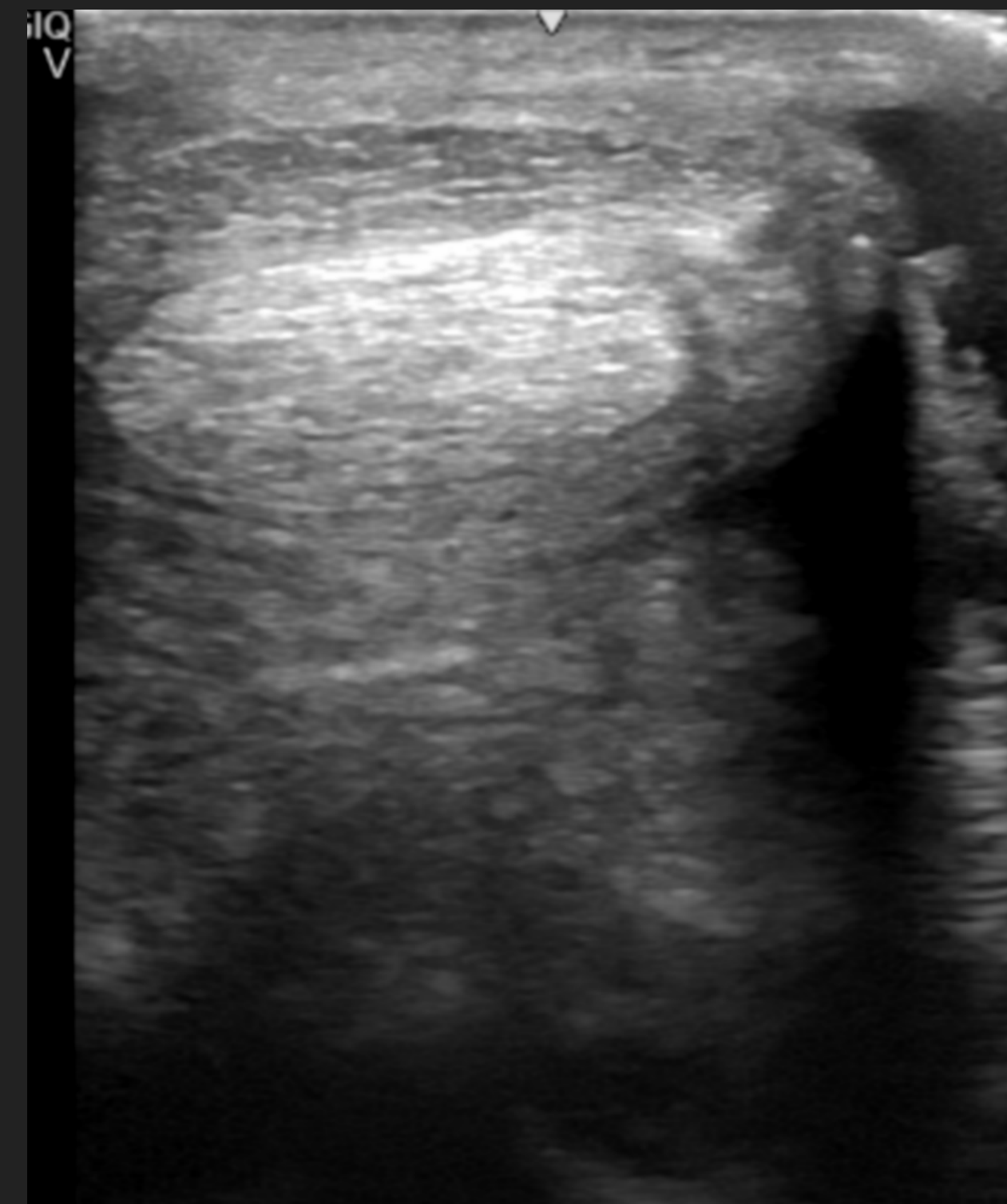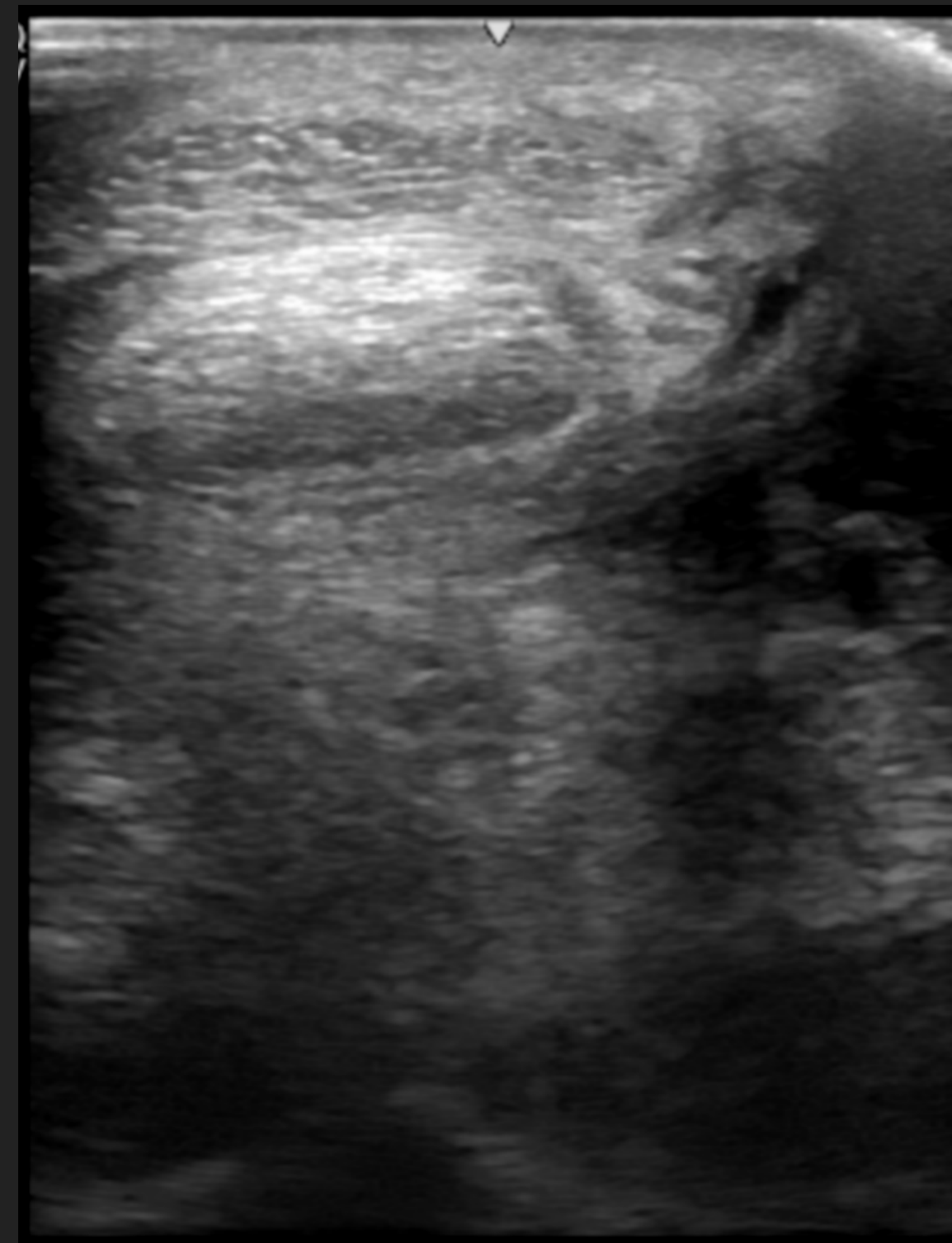

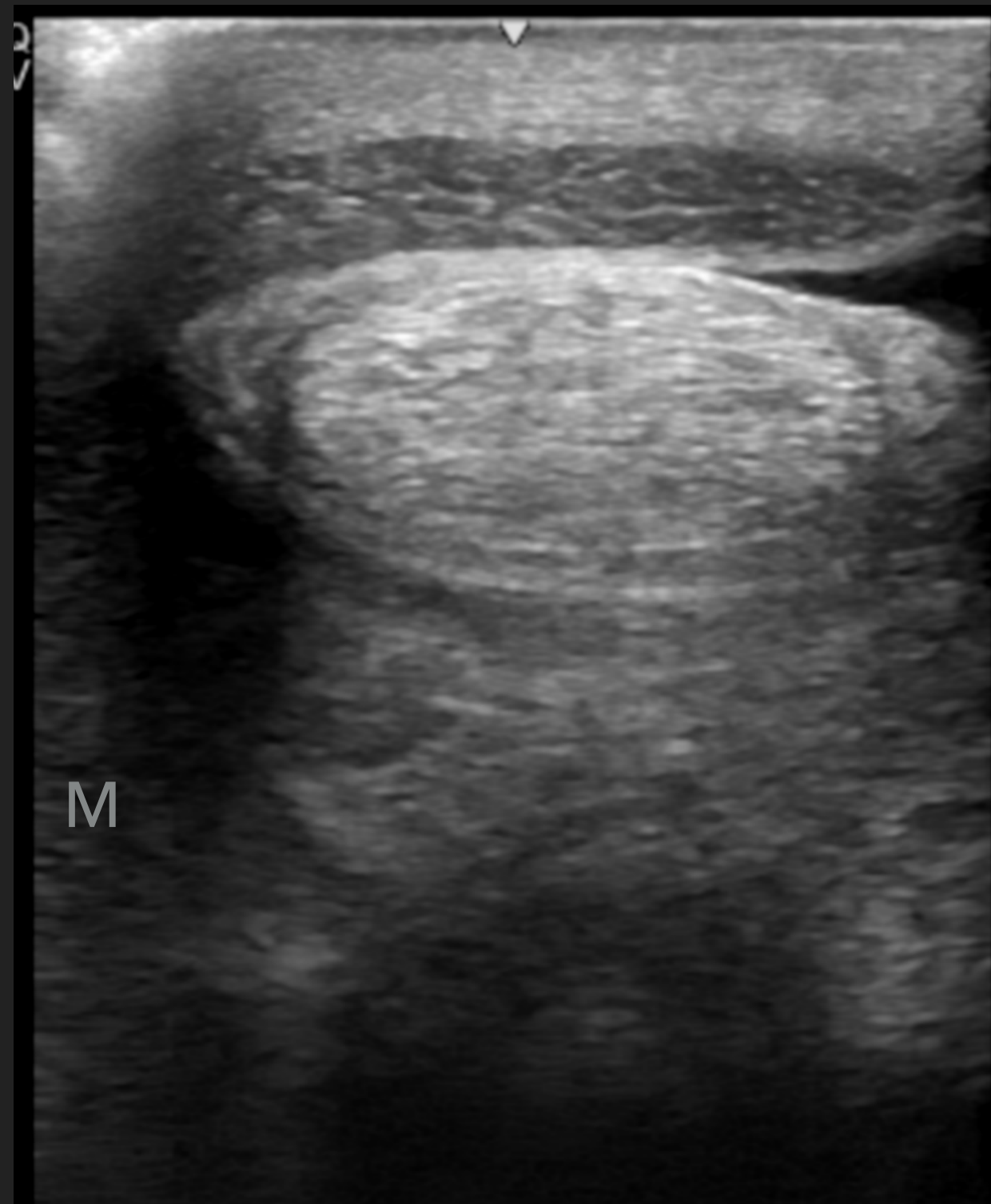
FLEXOR TENDONS /MANICA

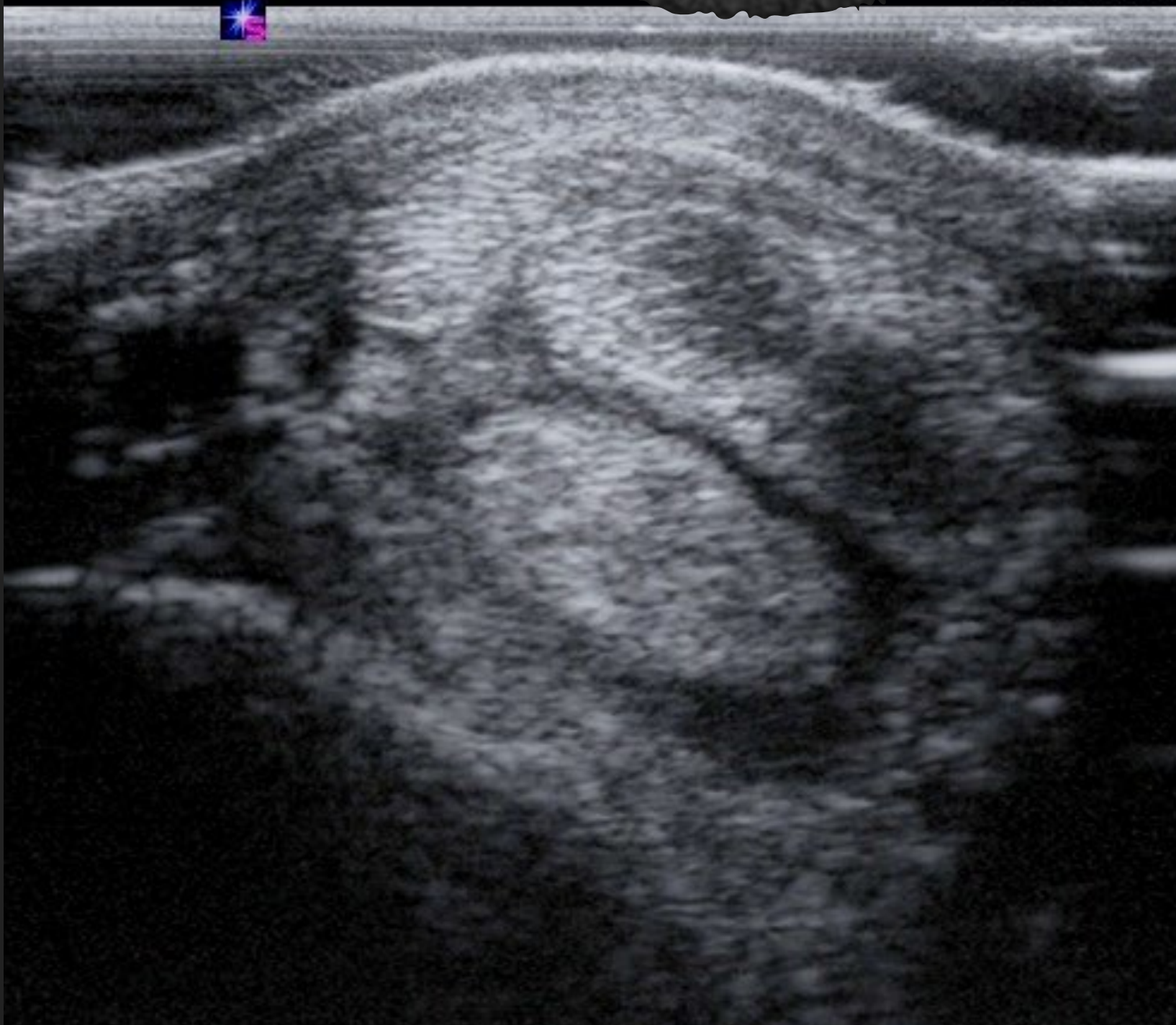
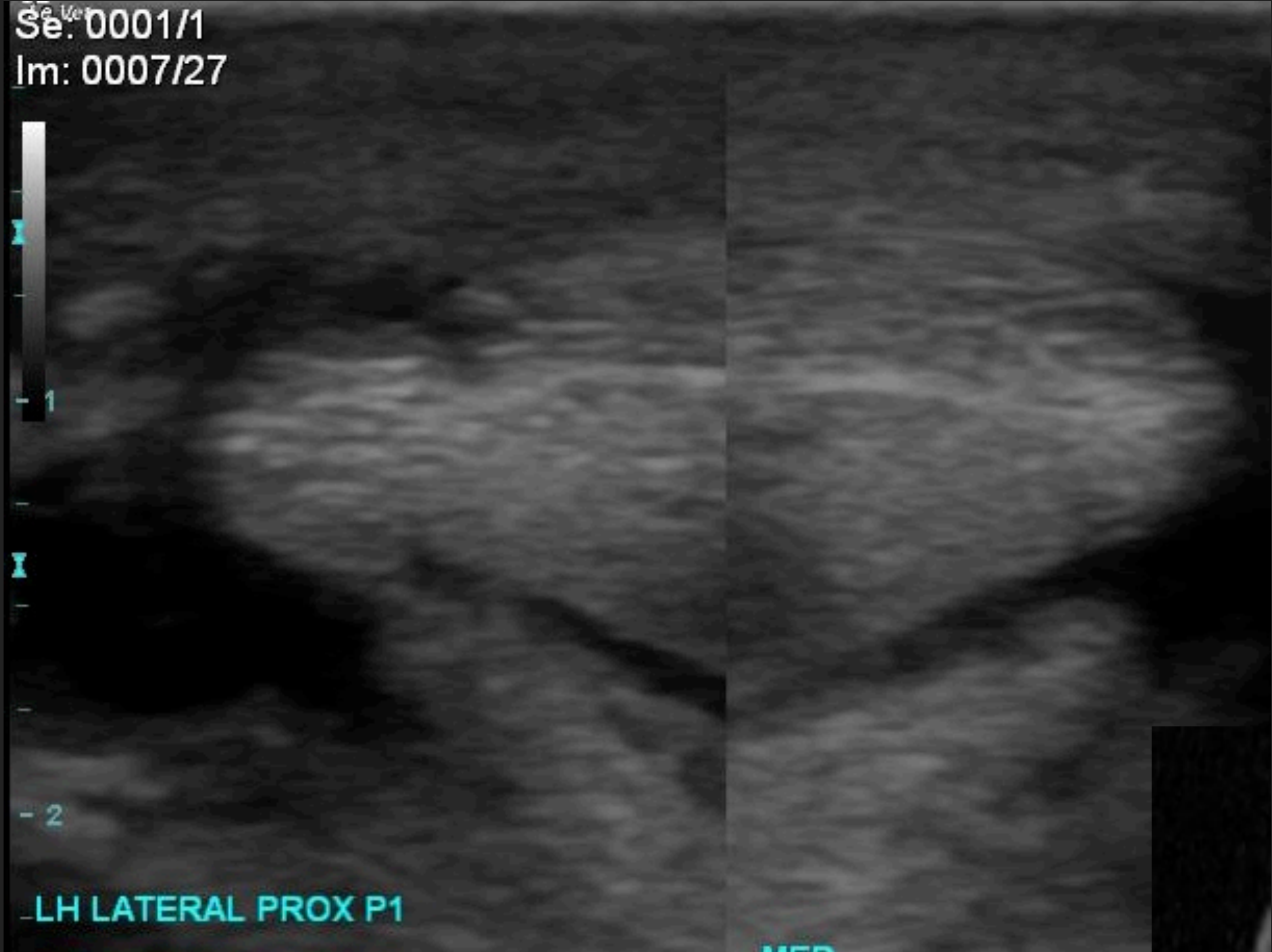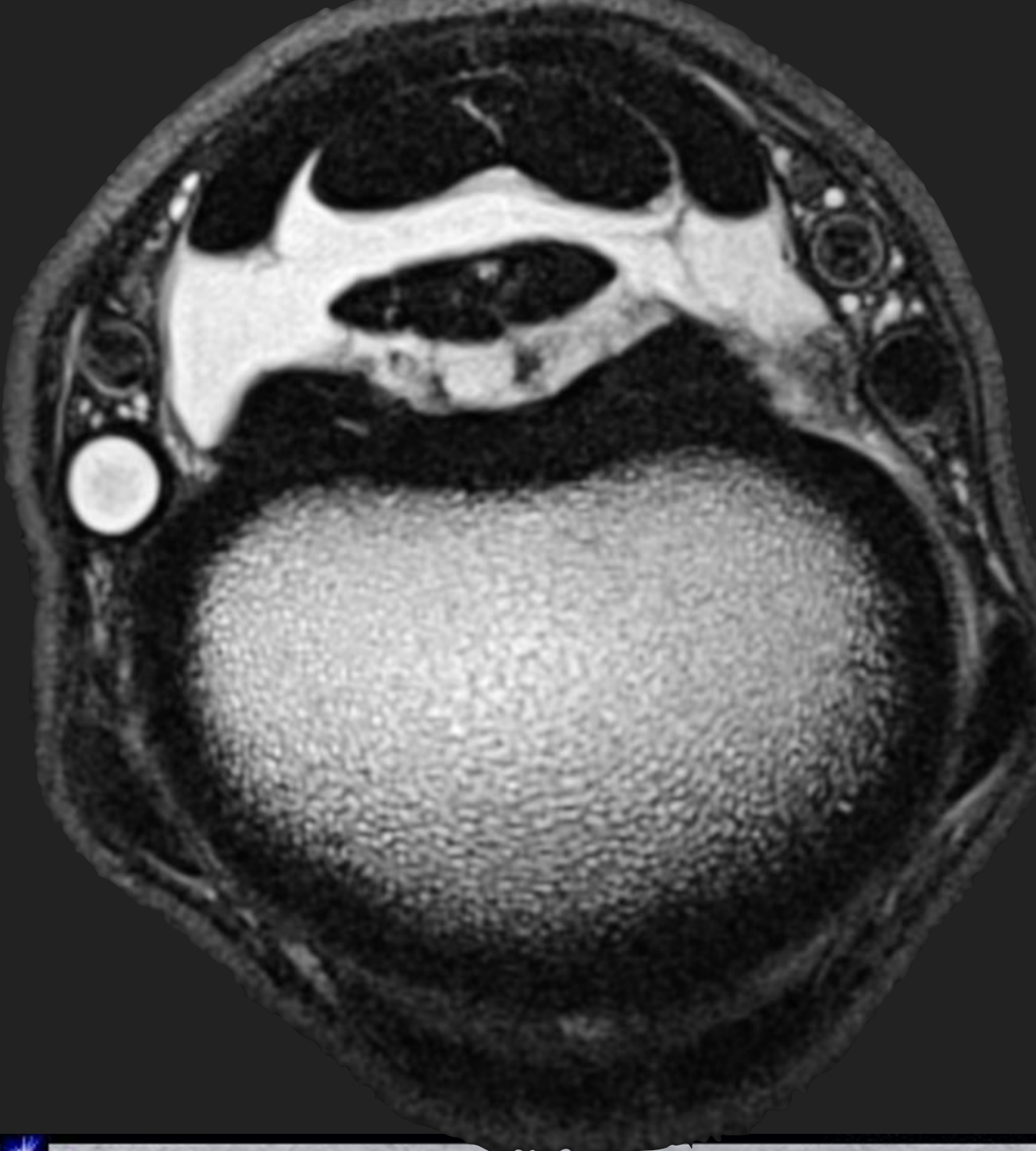
11 YO Hunter/Jumper RH 2/5 Lamé



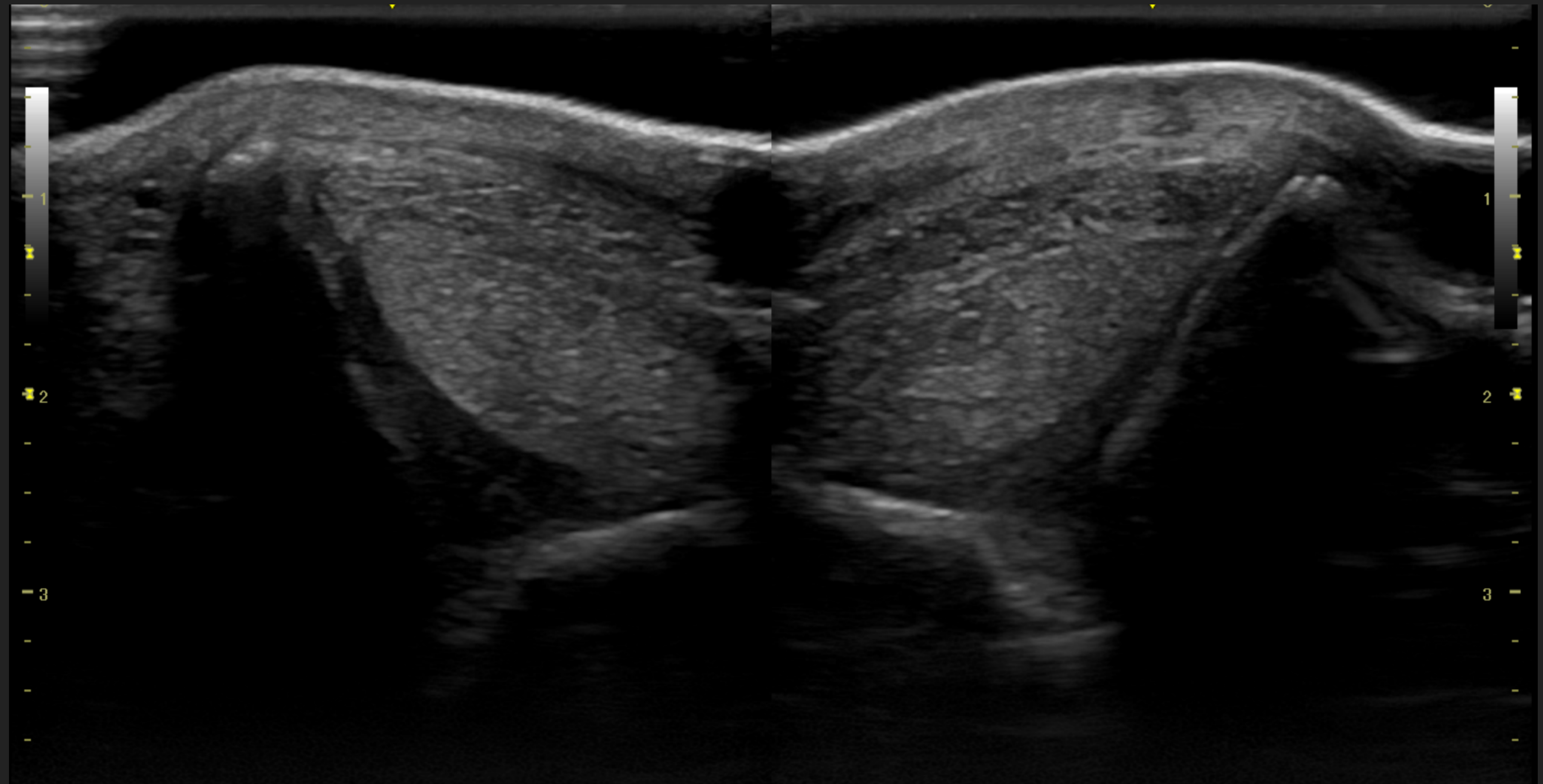
Normal



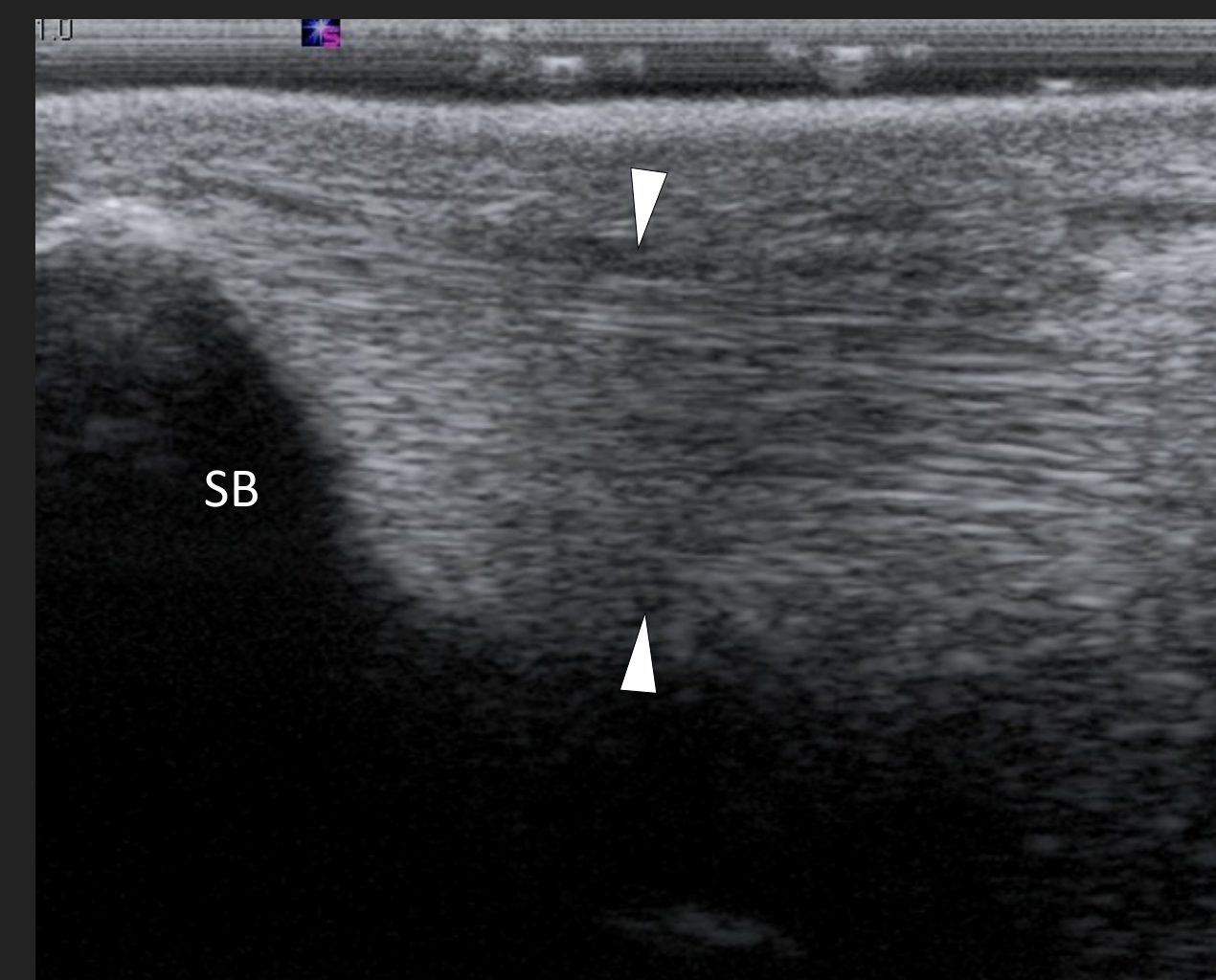
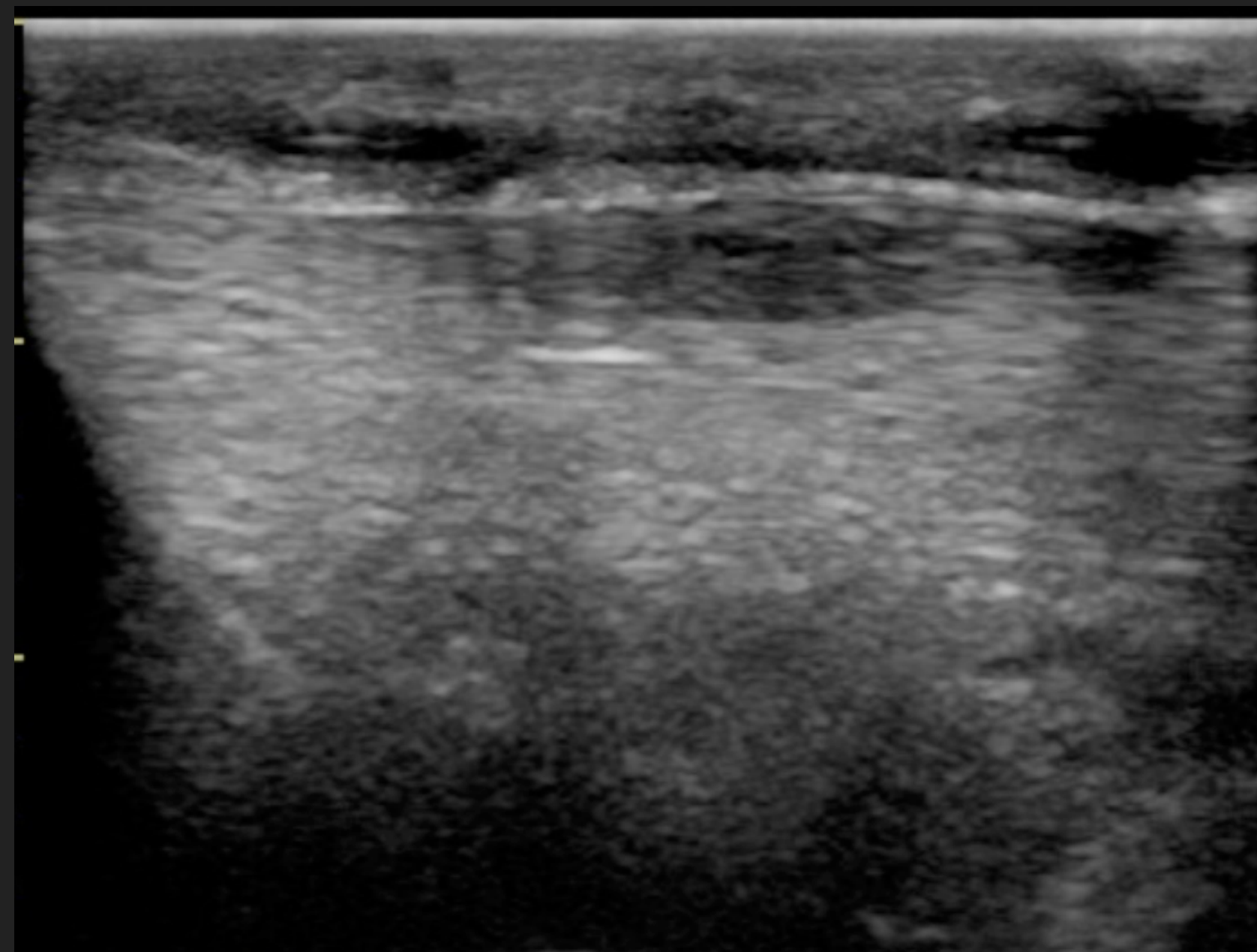
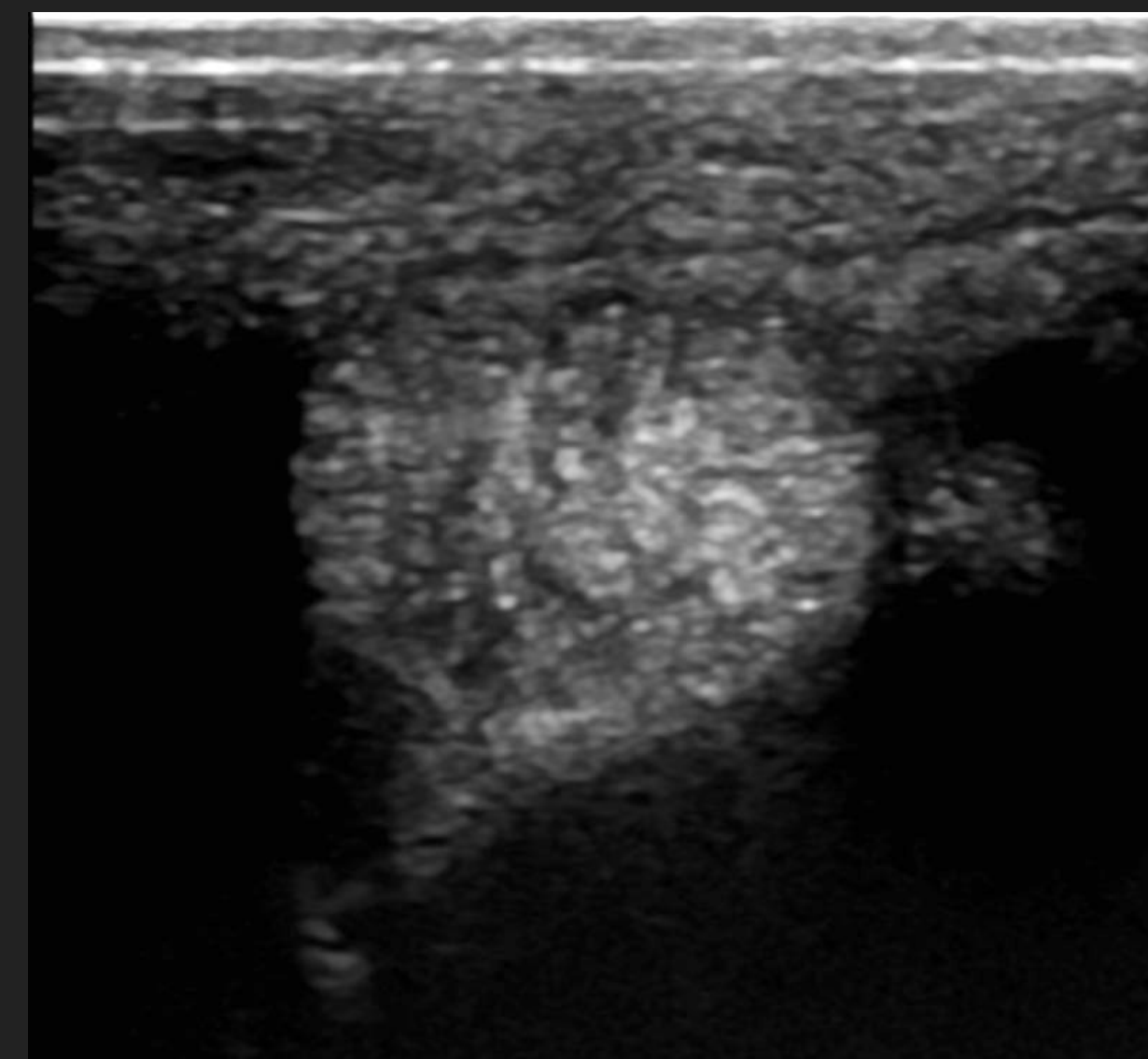
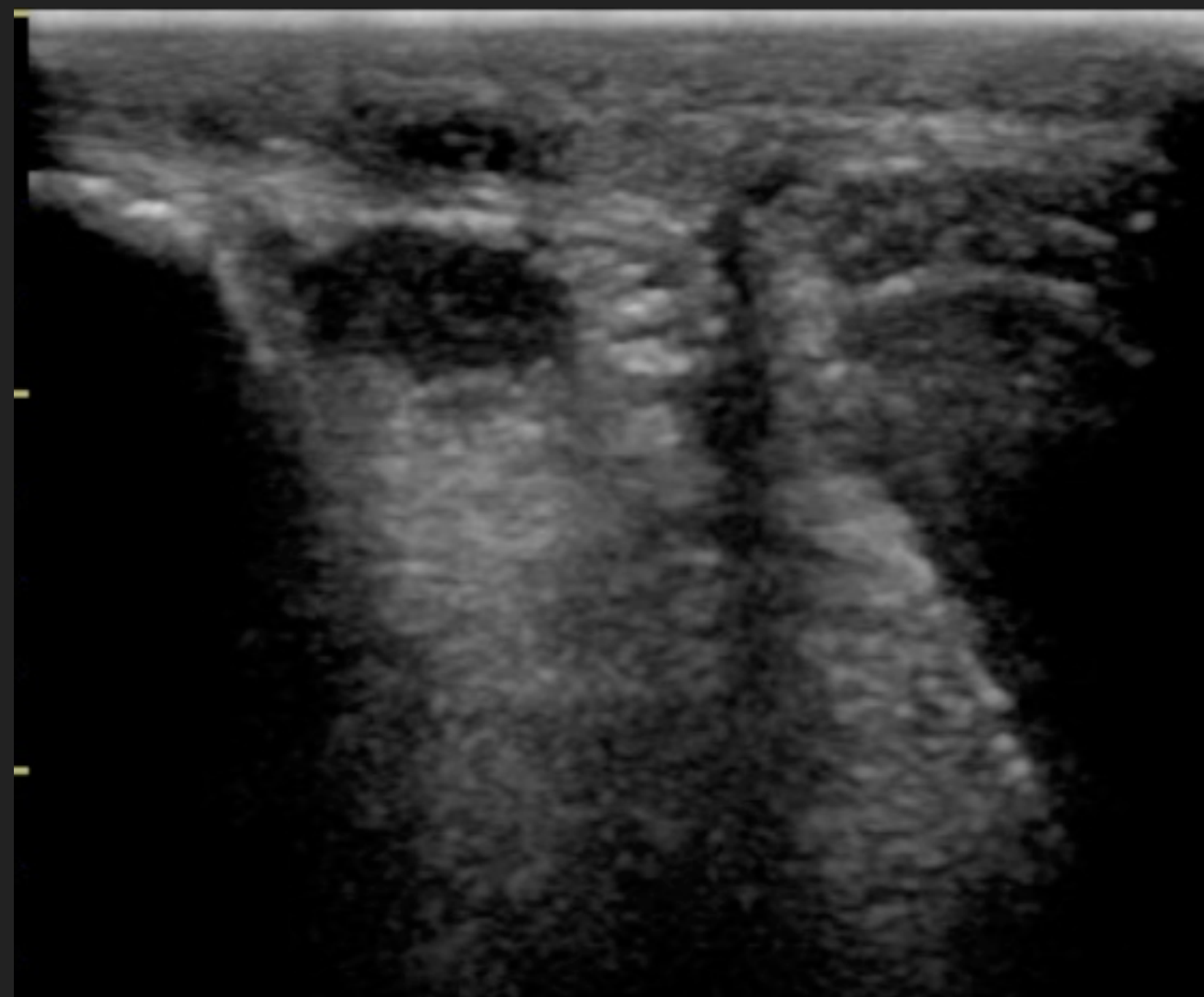
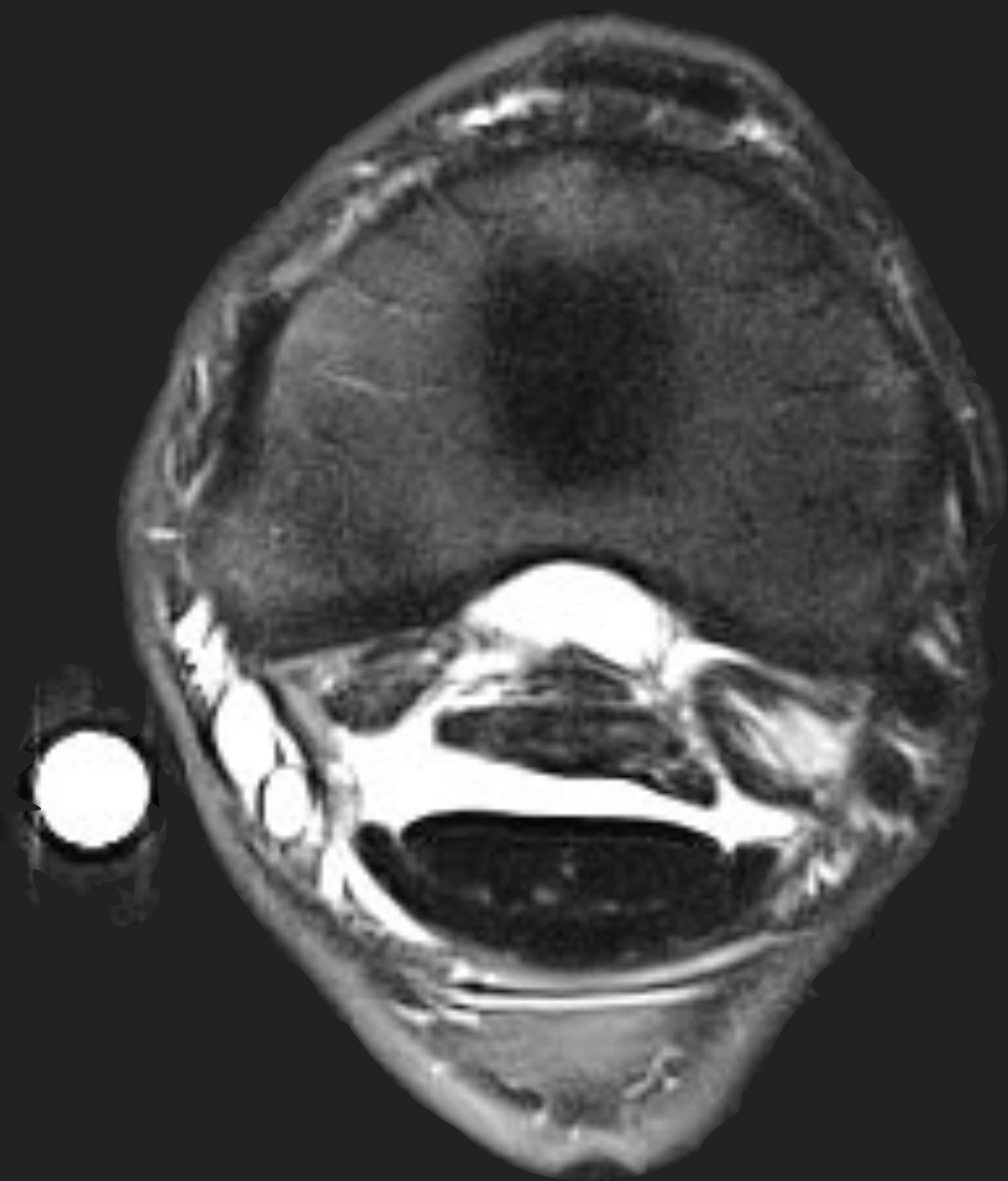
FLEXOR TENDONS: SDF



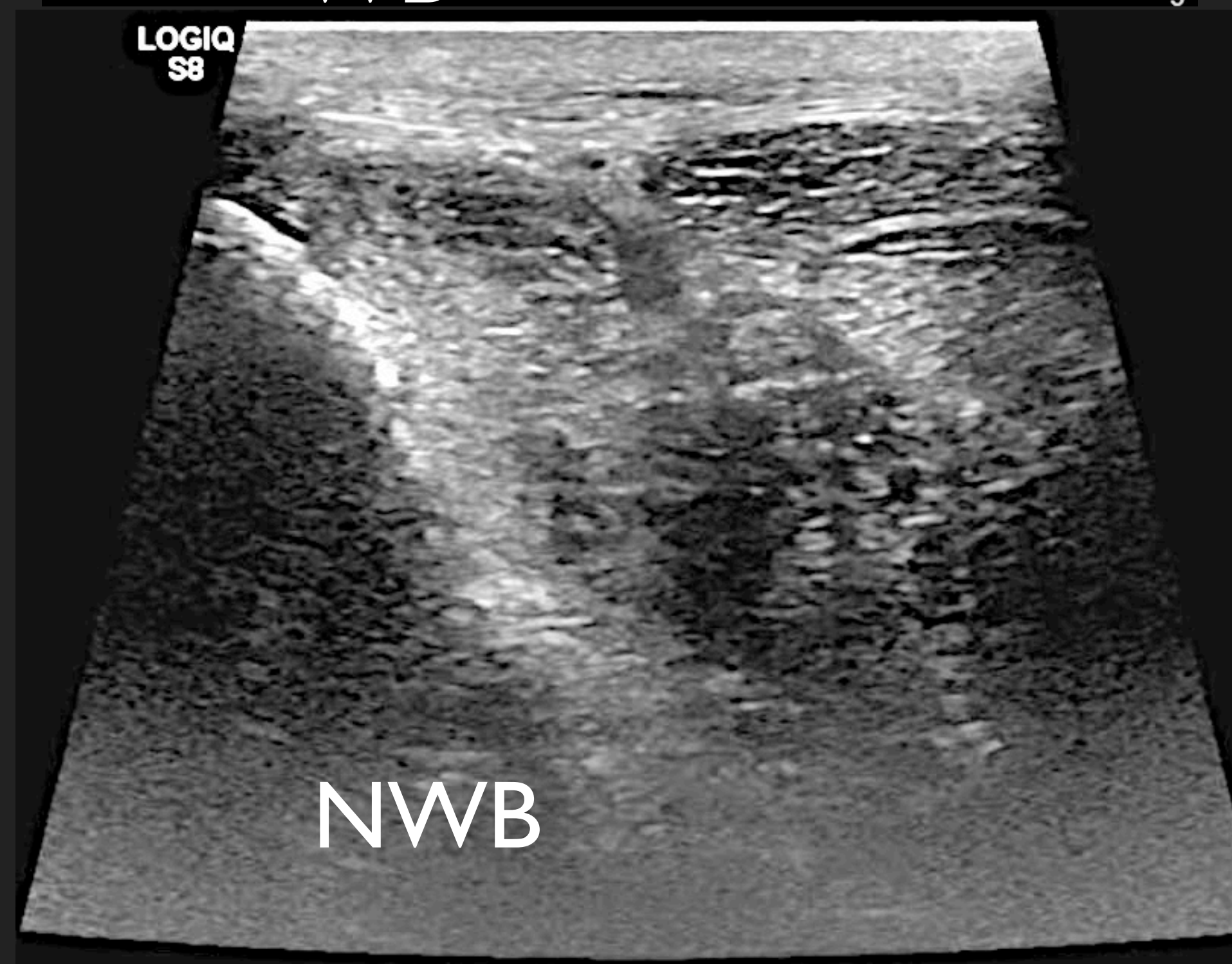
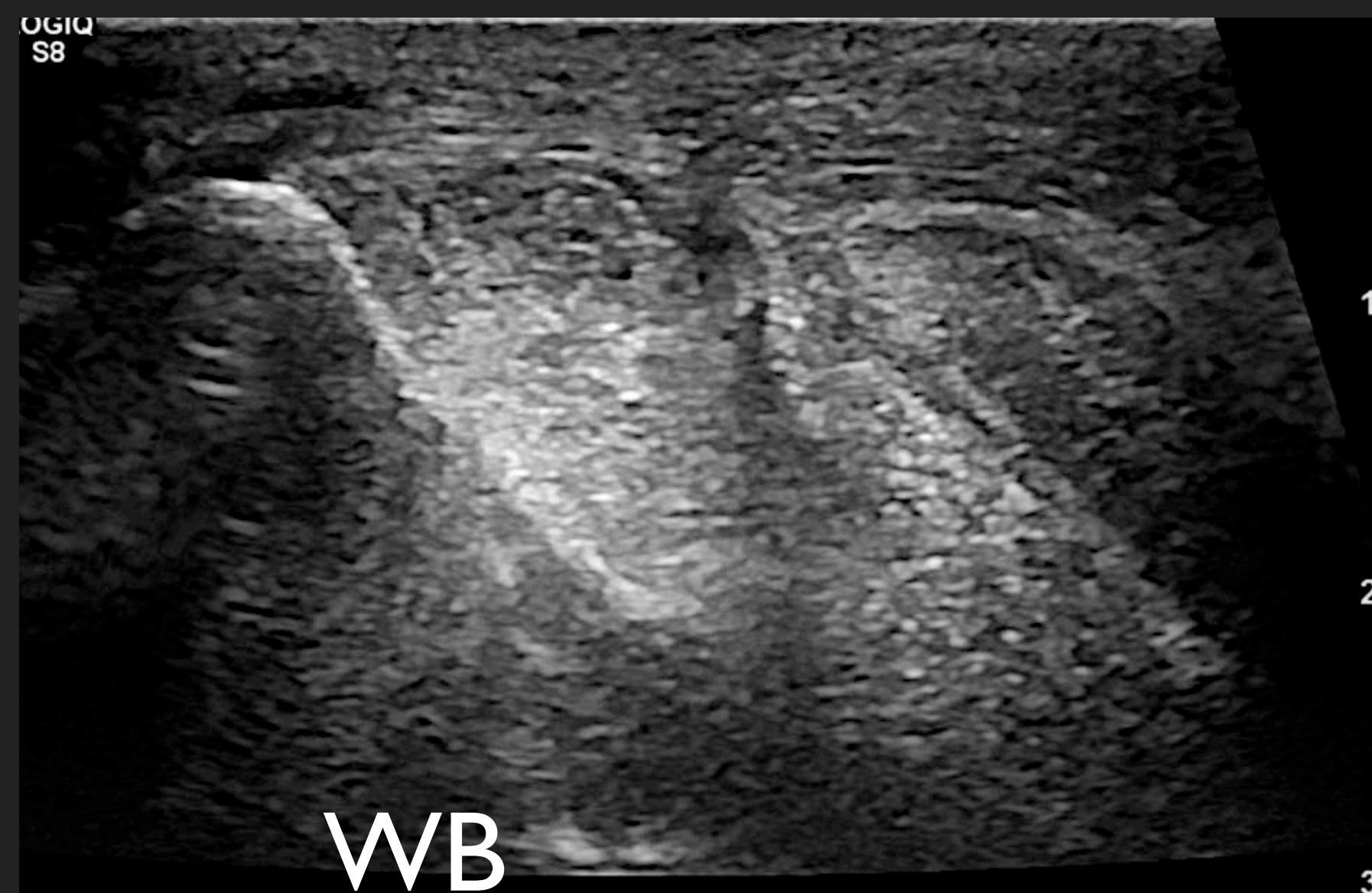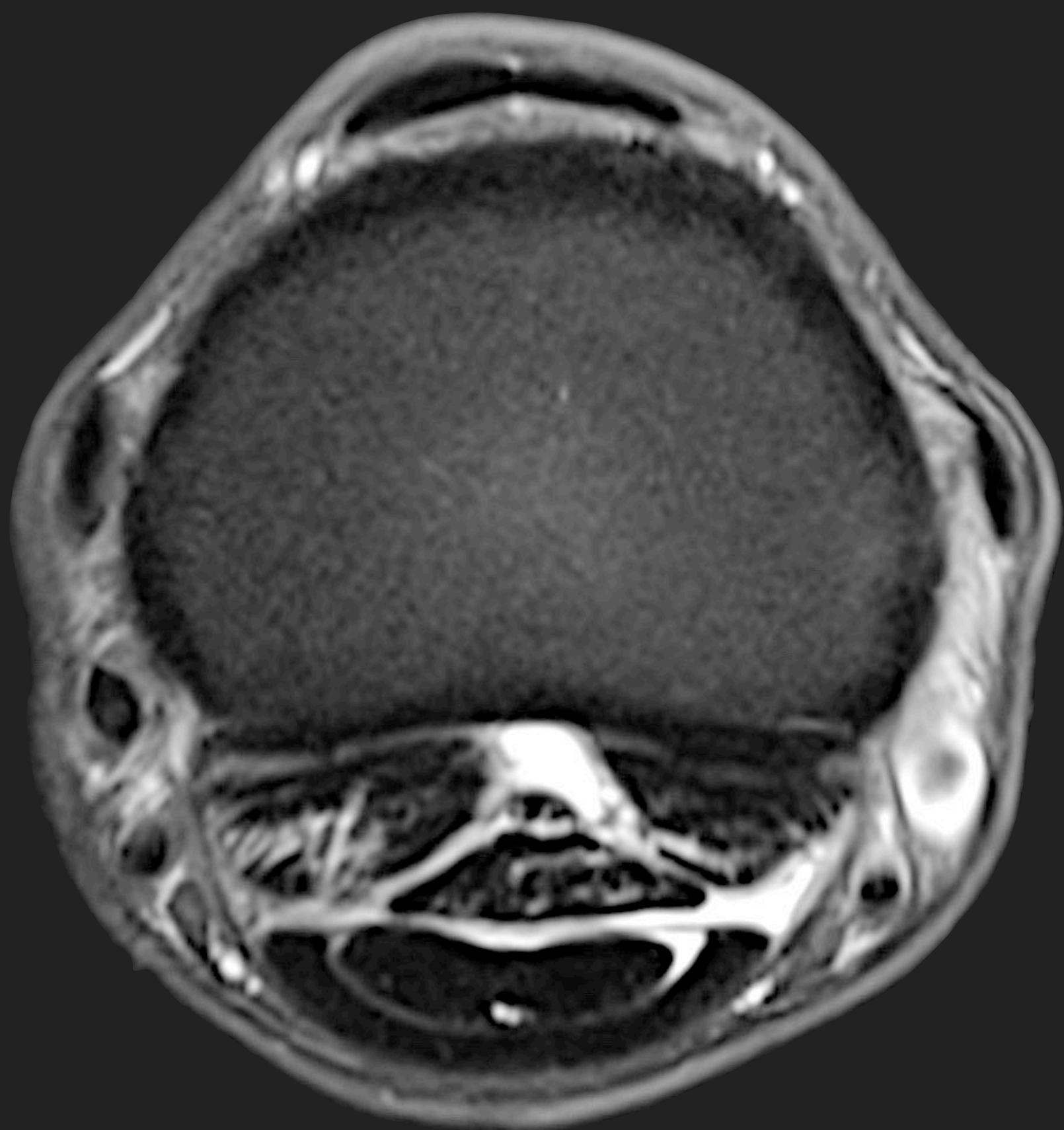
ANNULAR LIGAMENT



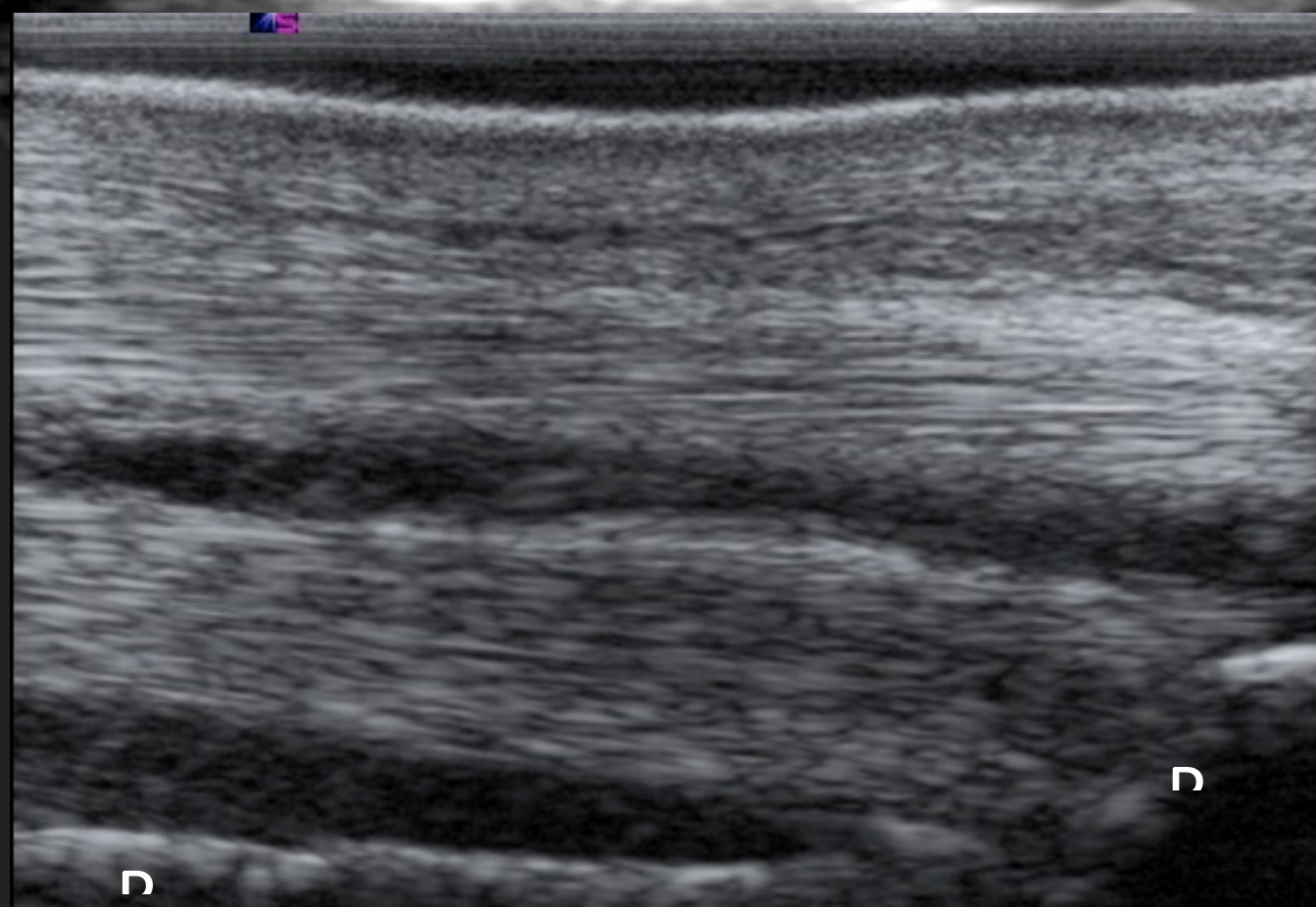
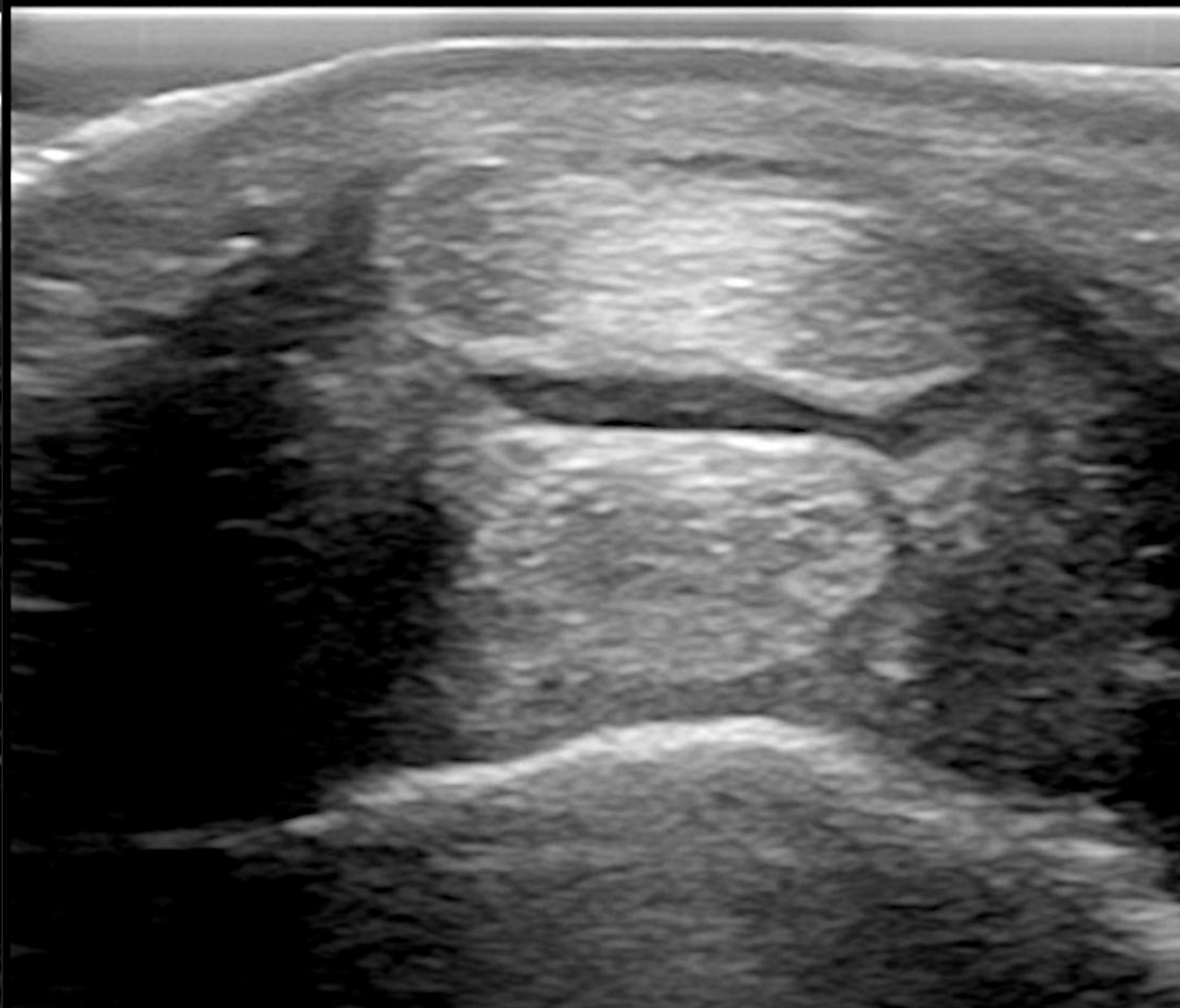
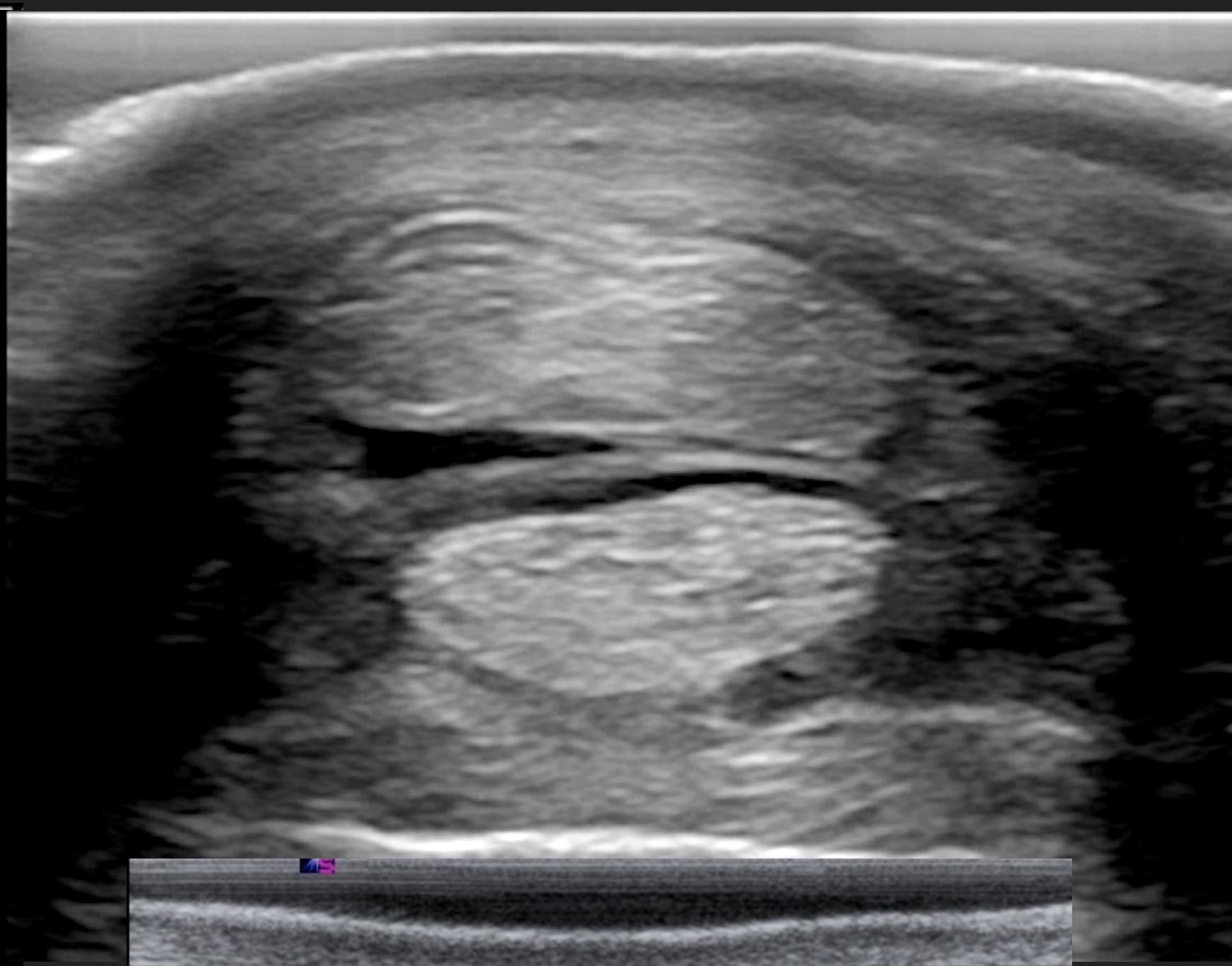
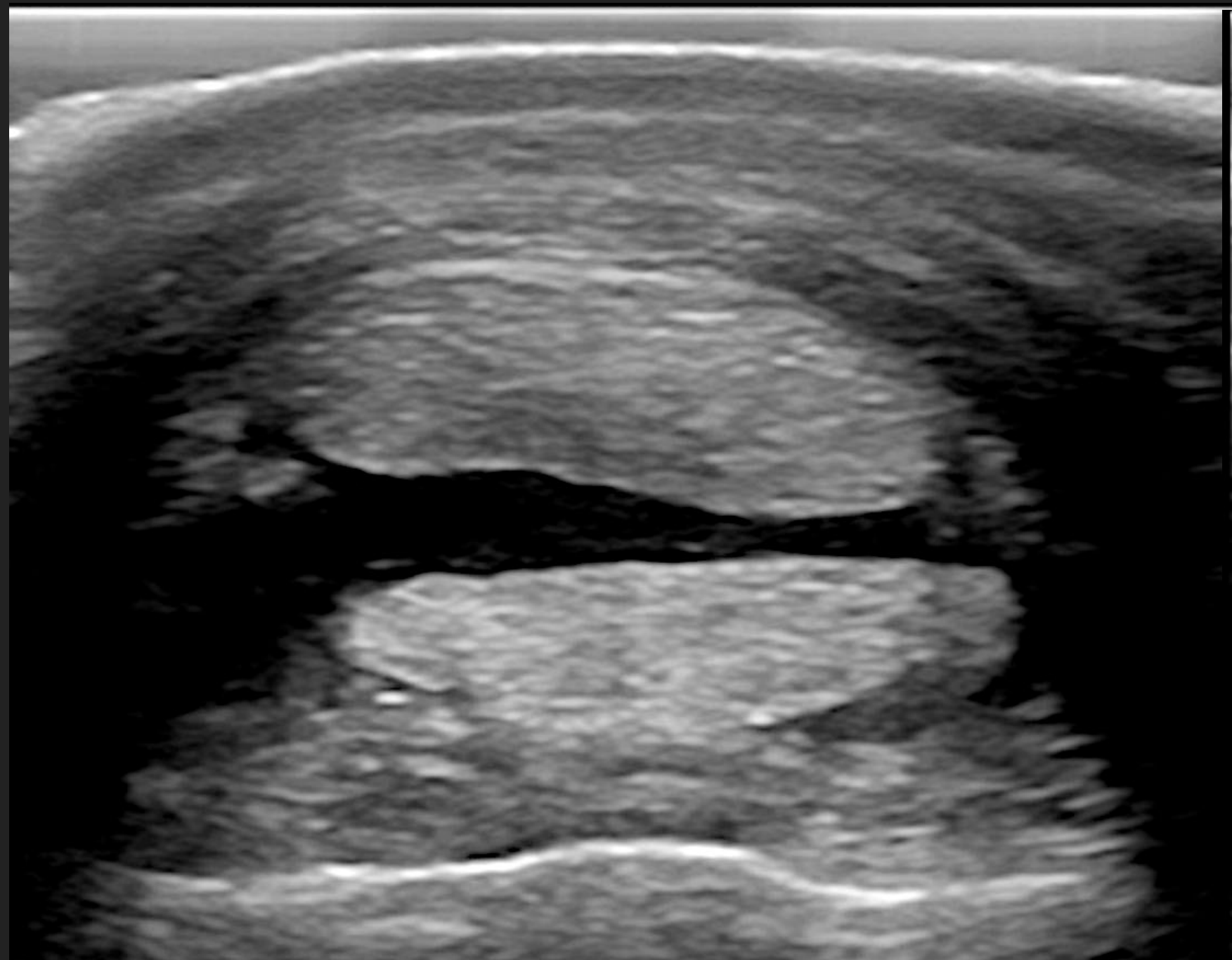
SESAMOIDEAN LIGAMENTS



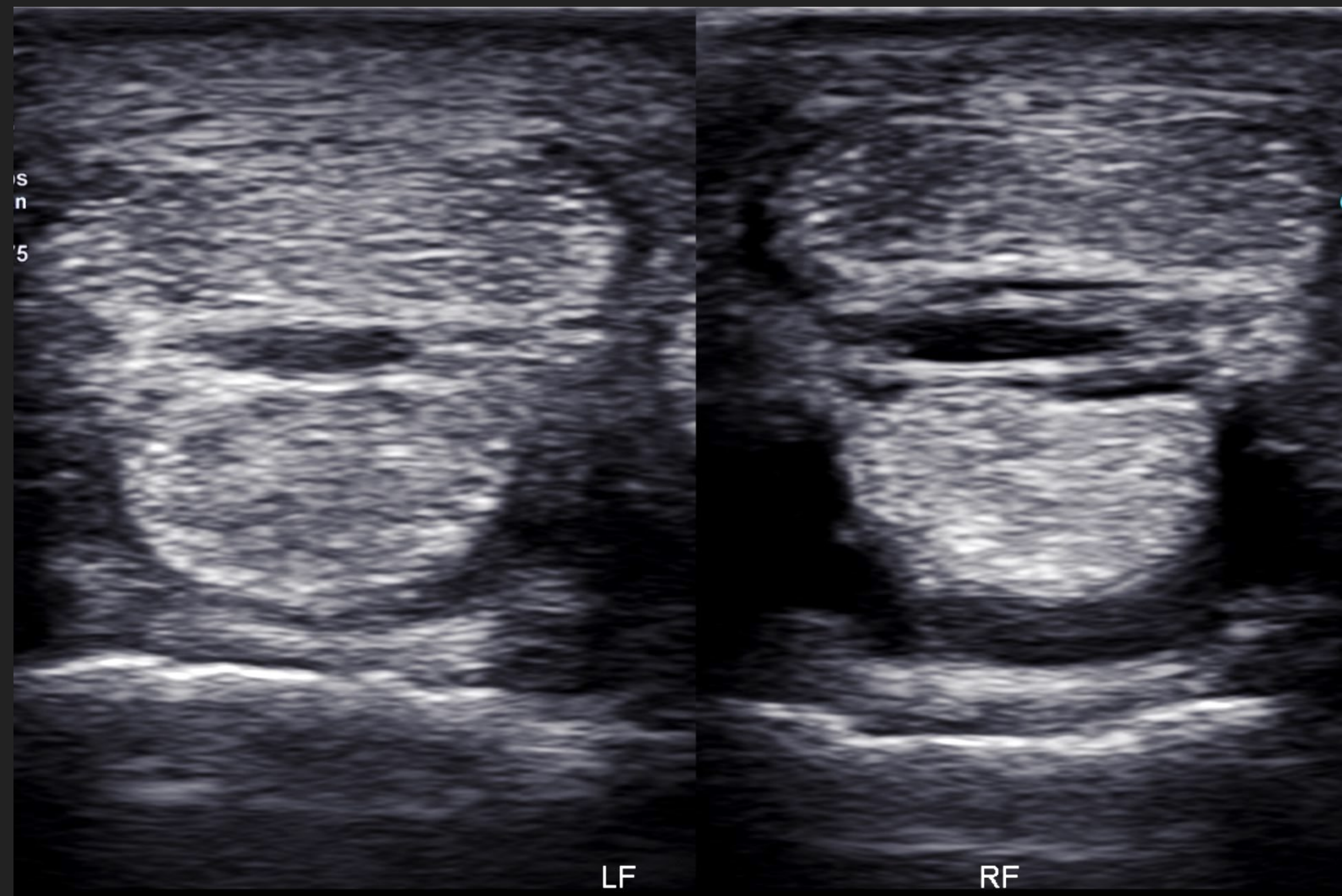
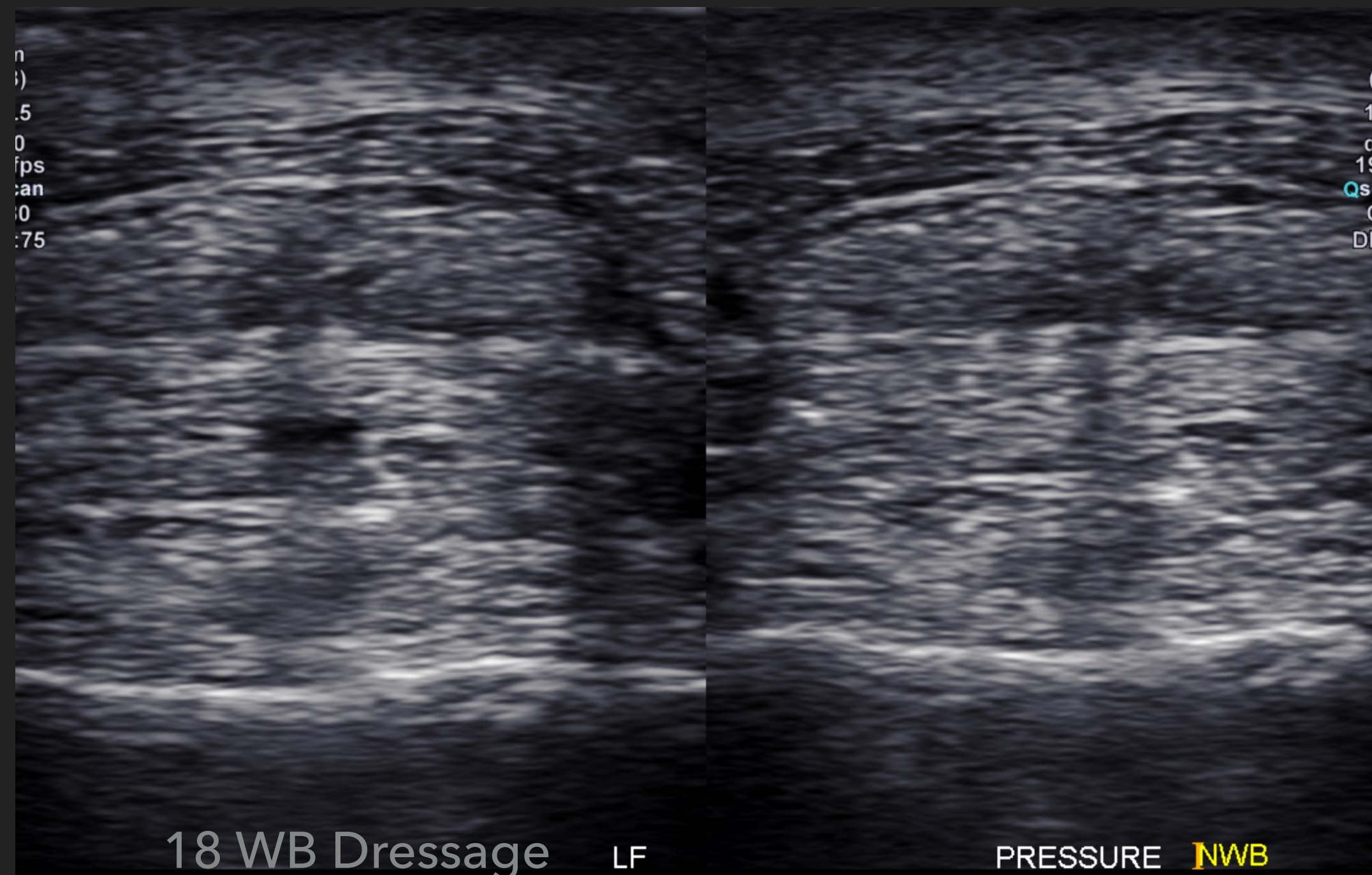
SESAMOIDEAN LIGAMENTS



SESAMOIDEAN LIGAMENTS: STRAIGHT

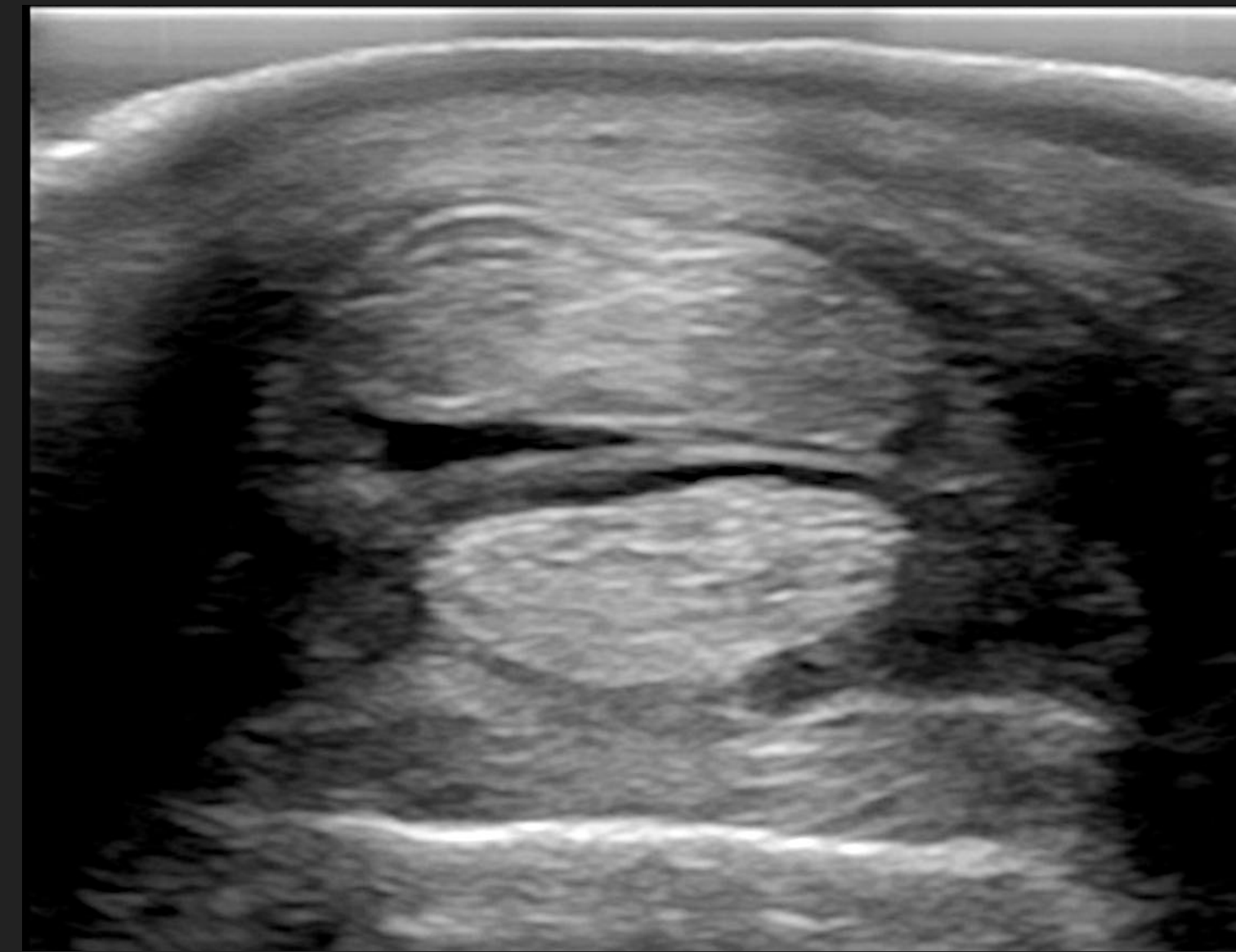


SESAMOIDEAN LIGAMENTS

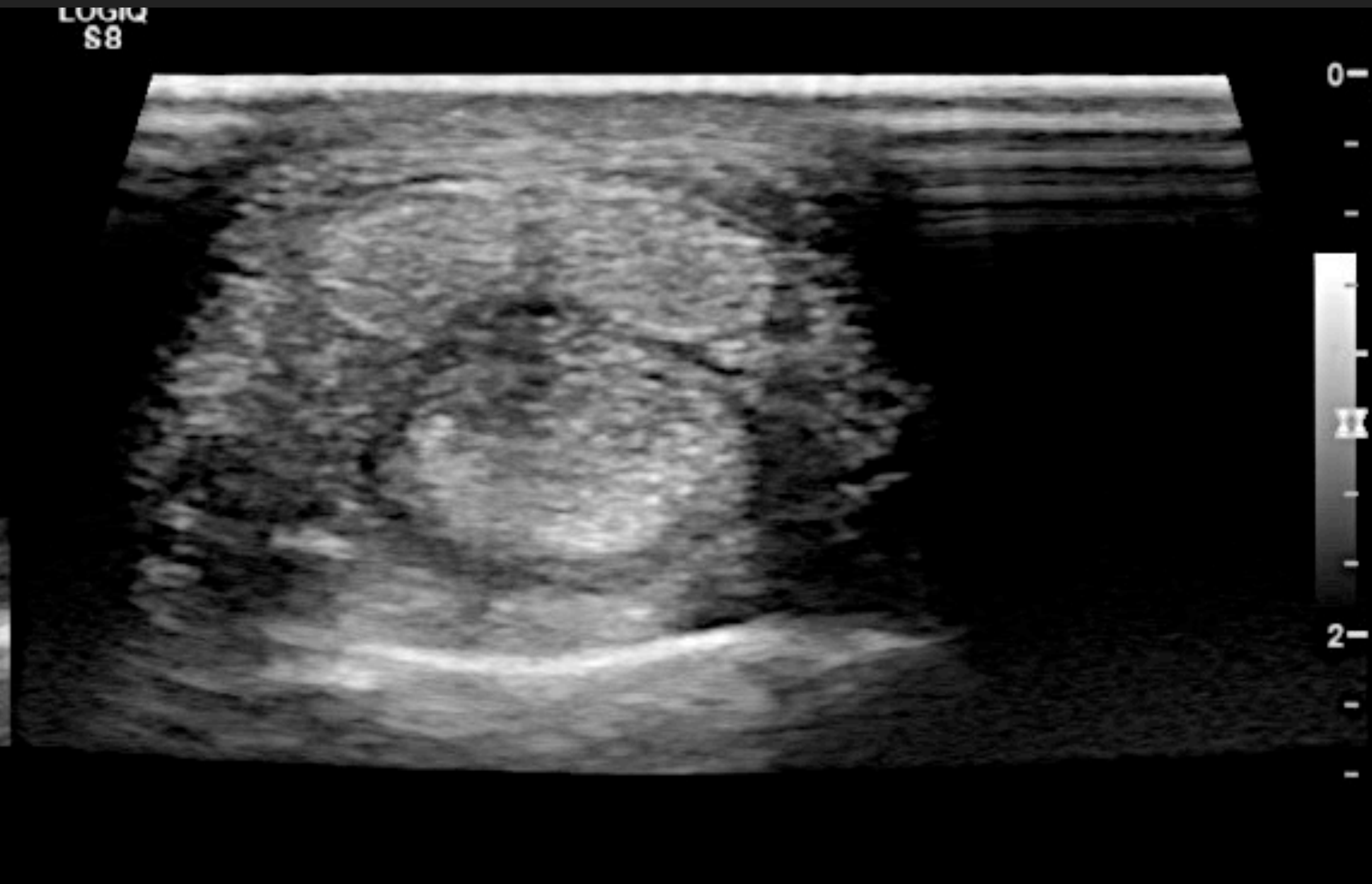
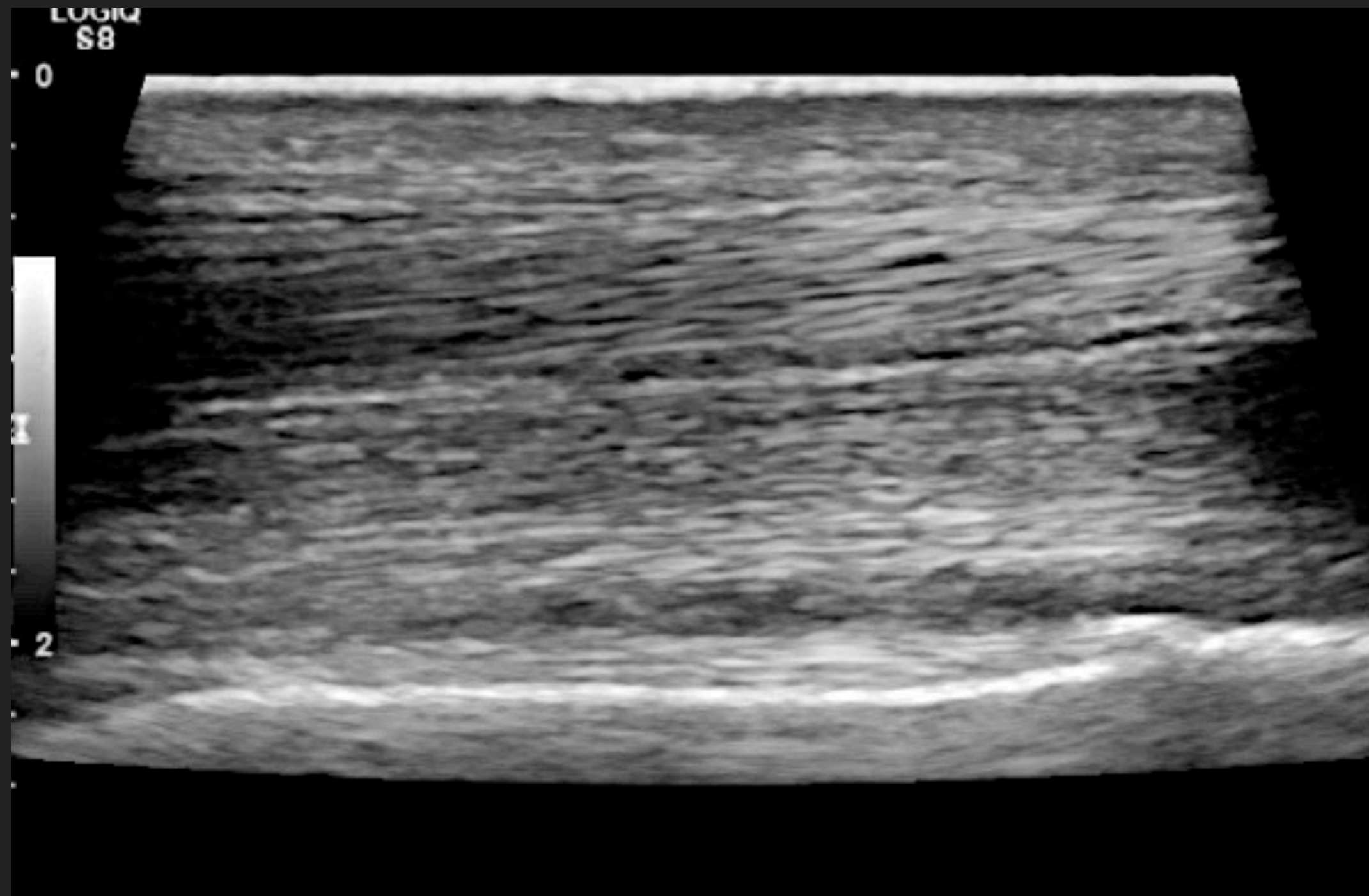


normal

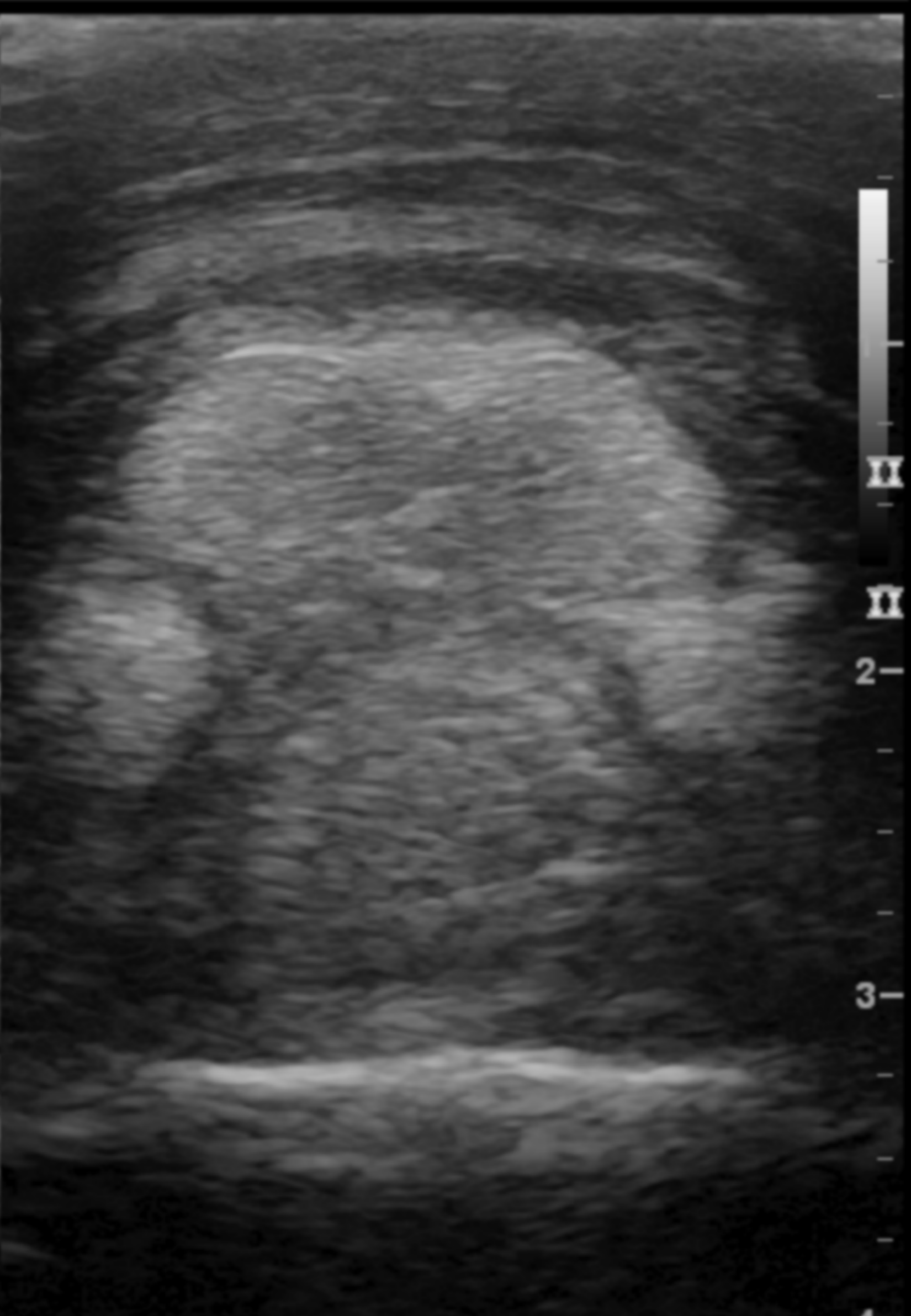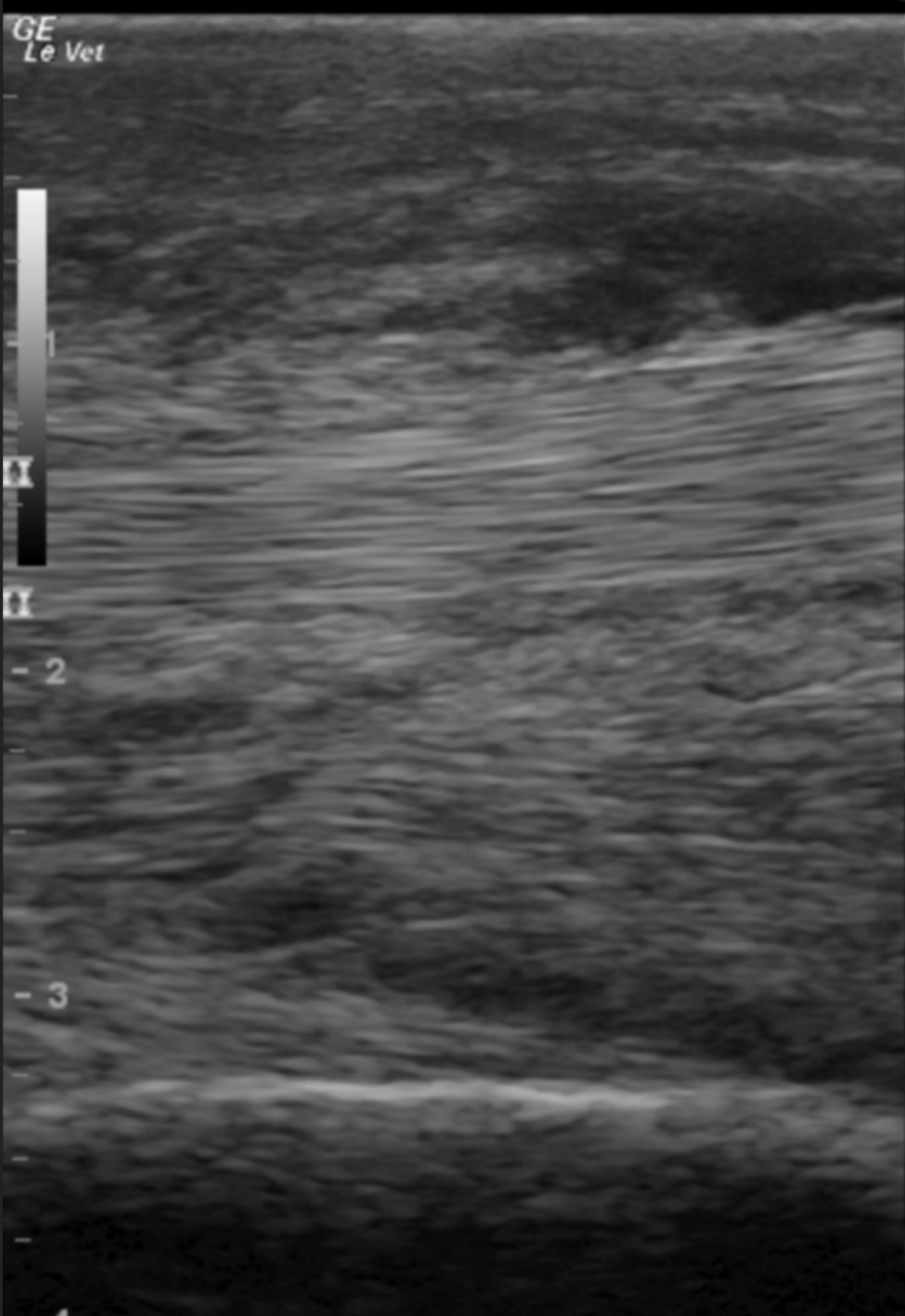
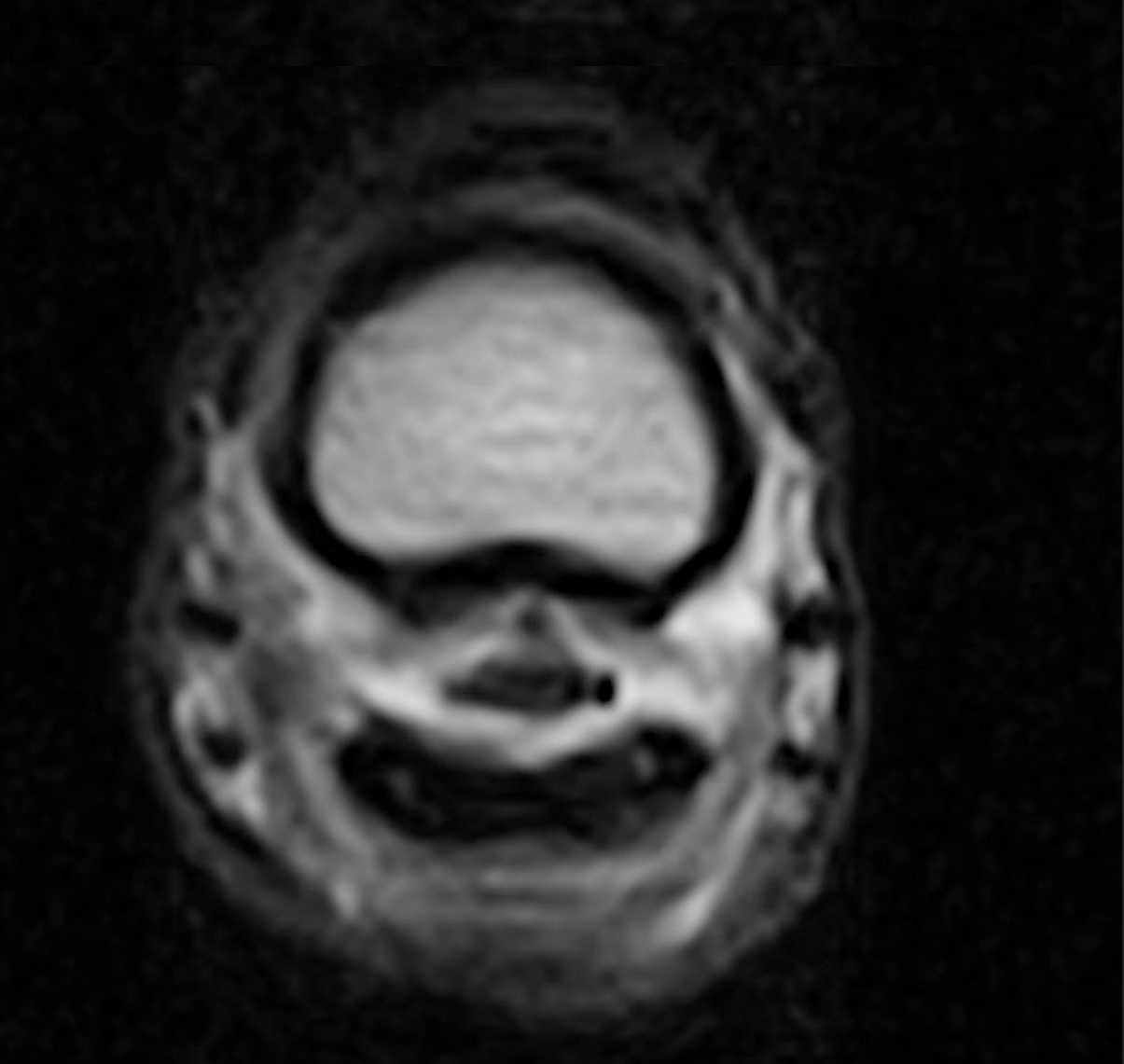
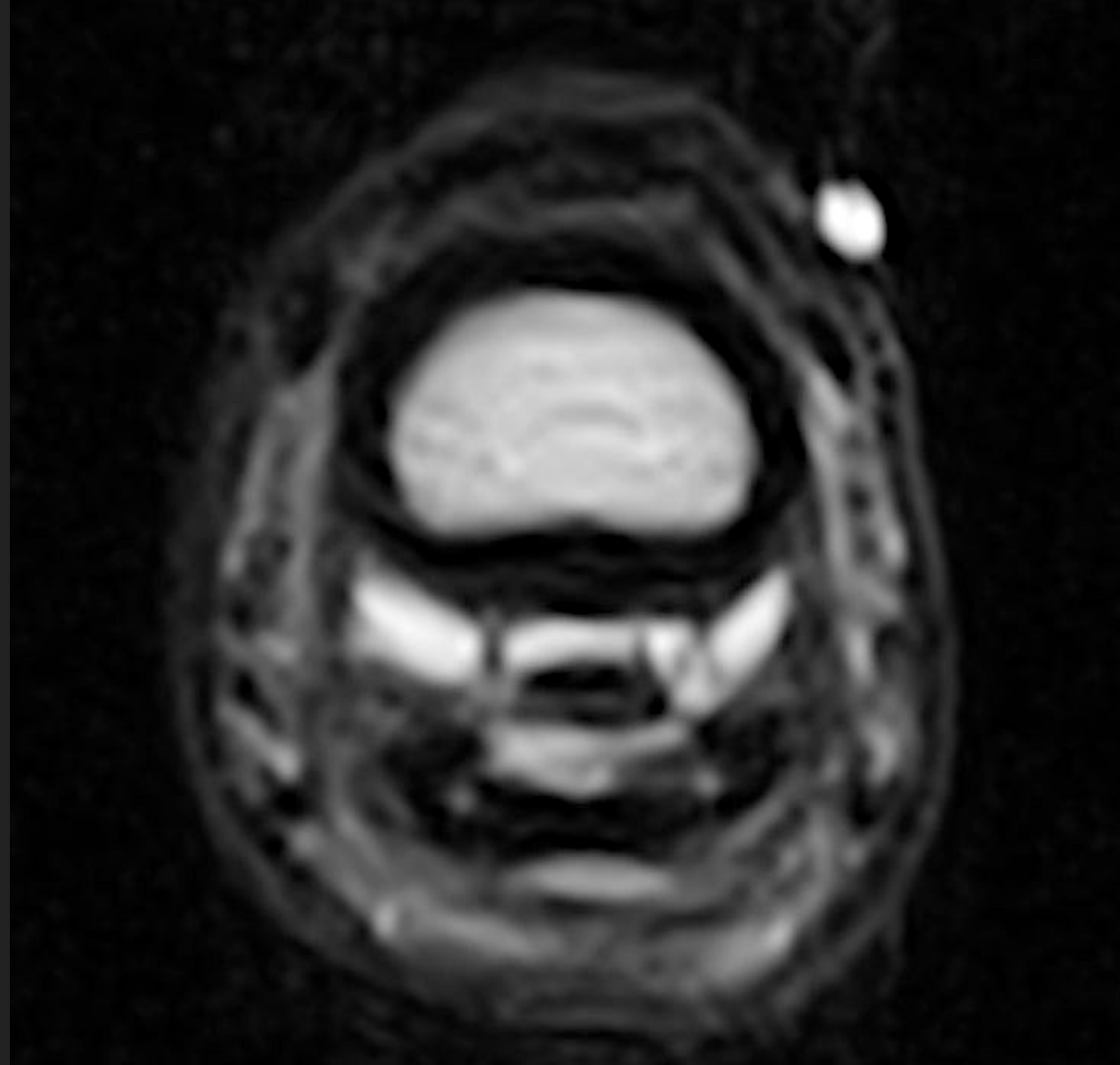
SESAMOIDEAN LIG: STRAIGHT



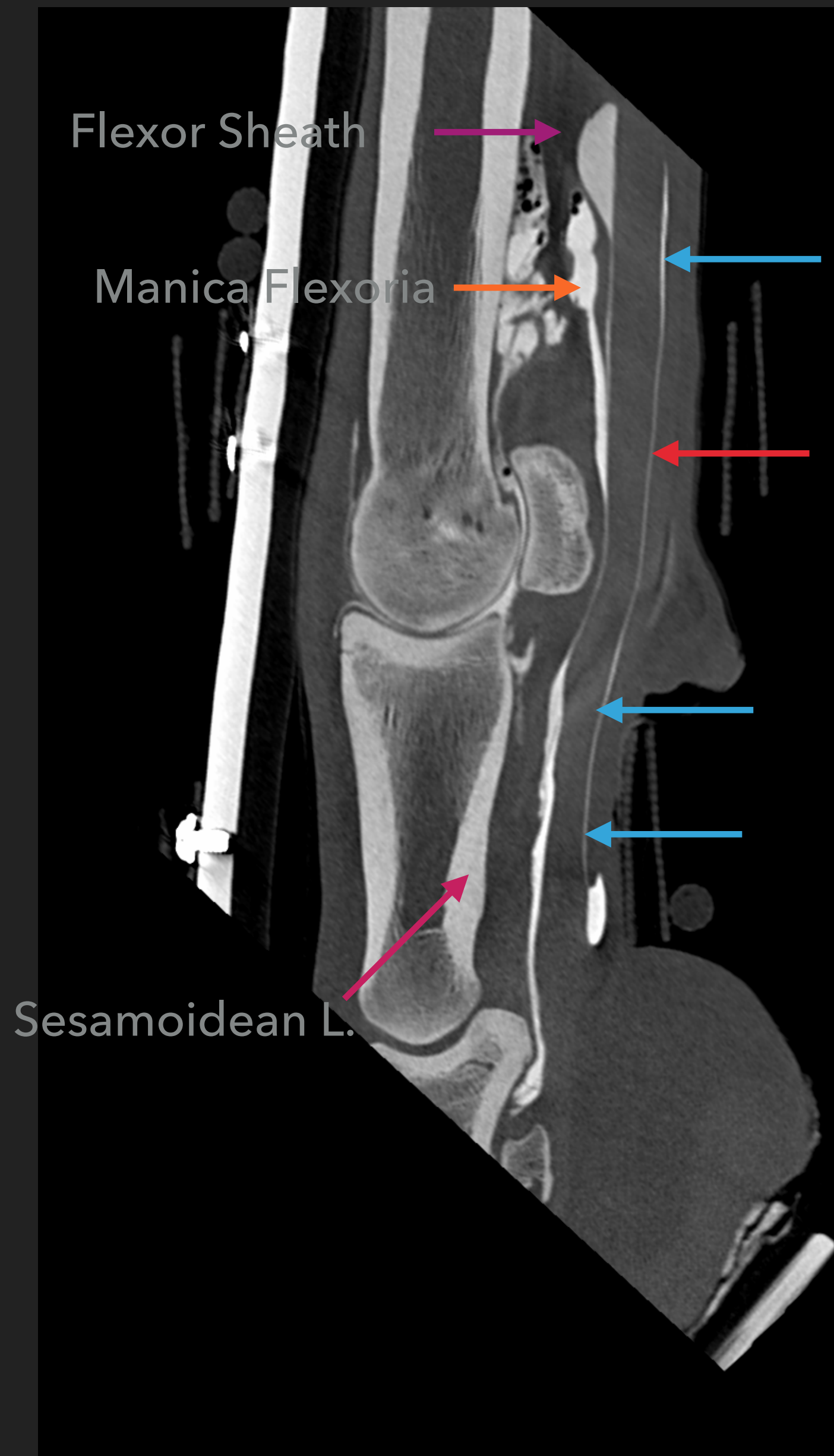
Normal



SHEATH



SUMMARY



deep digital flexor tendon

superficial digital flexor tendon

